

# The use of colour Doppler imaging to determine the effects of administration of butorphanol, medetomidine and ketamine on indices of feline ocular impedance

T. VRBOVSKA\*, L. HORNAKOVA, Z. DRAHOVSKA, M. KOZAR, A. TRBOLOVA

Small Animals Clinic, University of Veterinary Medicine and Pharmacy in Kosice, Kosice, Slovak Republic

\*Corresponding author: Vrbovska.Tatiana@gmail.com

**ABSTRACT:** Doppler impedance indices, such as the resistive index (RI) and pulsatility index (PI), are commonly used to characterise resistance to the flow in the vascular system. Chemical restraint can potentially affect these indices, although in some patients such restraint is necessary before ultrasonographic examination. The objective of this study was to compare ocular vascular velocity parameters, measured using Doppler imaging, in healthy conscious cats and in cats after administration of a combination of anaesthetics (butorphanol, medetomidine and ketamine). Twelve healthy cats of different breeds and both sexes were studied using Doppler imaging. The long posterior ciliary arteries in both eyes were examined. Mean comparison tests (paired and unpaired *t*-test) were used to determine whether any significant differences existed between right and left ocular indices and between sexes. A correlation study was applied between RI, PI and body weight. There were no significant differences in RI and PI between left and right eyes. Values also did not significantly differ among males and females. The RI and PI in long posterior ciliary arteries of cats anaesthetised with butorphanol, medetomidine and ketamine were significantly lower than those of healthy conscious cats. There was no correlation between impedance indices and body weight.

**Keywords:** anaesthesia; cat; eye; posterior ciliary artery; resistive index; pulsatility index

Doppler ultrasound has become an accepted and routine method for the investigation of blood haemodynamics in both humans and animals since it can rapidly and non-invasively provide information regarding many vascular diseases (Lee et al. 2004). The technique provides dynamic real-time anatomical vascular information; moreover, it allows for the detection of the presence, direction, and type of blood flow into a vessel (Szatmari et al. 2001).

An understanding of the normal Doppler signs of each blood vessel is important in their identification because Doppler signals are fairly specific to a par-

ticular vessel (Szatmari et al. 2001). Doppler imaging of the ophthalmic vasculature is possible in many ocular and retrobulbar vessels including the external and internal ophthalmic artery, anterior ciliary artery, short and long ciliary arteries, and primary retinal arteries (Gelatt-Nicholson et al. 1999a).

Doppler flow indices (impedance indices), such as the resistive index (RI) and the pulsatility index (PI), are commonly used to characterise blood flow (Ferrandis et al. 2013). RI or Pourcelot ratio is an indicator of the resistance of an organ to perfusion. It is a measurement designed to interpret the shape of the waveform of a vessel (Pozniak et al. 1988),

Supported by the Scientific Grant Agency of Ministry of Education, Science, Research and Sport of the Slovak Republic (VEGA; Grant No. 1/0225/15).

and is defined as the ratio of the peak systolic velocity and the end diastolic velocity of the blood flow. RI is calculated with the following formula (Macri et al. 2015):

$$RI = PSV-EDV/PSV$$

where: RI = resistive index; PSV = peak systolic velocity; EDV = end diastolic velocity

A high RI correlates to increased distal vascular resistance and decreased perfusion (Liu et al. 1997). PI, a parameter closely related to the RI, has also been shown *in vitro* to be related to vascular resistance (Legarth and Thorup 1989). PI, which decreases with distance from the heart, is equal to the difference between the peak systolic velocity and the minimum diastolic velocity divided by the mean velocity during the complete cardiac cycle (Gelatt-Nicholson et al. 1999b). Analysis of the Doppler spectra and calculation of RI and PI provides unique physiological information related to peripheral resistance, vascular compliance, conductance and transmural pressure (Ostrowska et al. 2016). Measurement of ocular RI and PI is especially interesting in animals suffering from diseases such as diabetic retinopathy, glaucoma and systemic hypertension (Gelatt-Nicholson et al. 1999b; Goncalves et al. 2008), which result in significant alterations in the ocular vascular pattern. The evaluation of ocular vascularisation can also provide information on neovascularisation in cases of neoplasms and it is important for determining a patient's prognosis and in choosing suitable therapy (Gonzalez et al. 2001). This is in agreement with a report by Choi et al. (2011), who determined that also in cases of glaucoma, some anti-glaucoma drugs could affect ocular blood flow in the medial long posterior ciliary artery. This finding is important for the investigation and treatment of glaucoma as anti-glaucoma treatments lower intraocular pressure, while increasing ocular blood flow. An increase in ocular blood flow (especially in episcleral vessels) causes a decrease in intraocular pressure – according to the Goldmann equation (Nassr et al. 2009):

$$P_o = (F/C) + P_v$$

where:  $P_o$  = intraocular pressure;  $F$  = aqueous formation ( $\mu\text{l}/\text{min}$ );  $C$  = facility of outflow ( $\mu\text{l}/\text{min}/\text{mm}/\text{Hg}$ );  $P_v$  = episcleral venous pressure

There also exists the possibility of judging whether the effects of anti-glaucoma drugs on ocular vascular resistance are detrimental or beneficial to the eye (Choi et al. 2011).

The cardiovascular effects of sedation and anaesthesia should also be taken into account while interpreting the results of haemodynamic and vascular investigations for diagnostic or prognostic purposes (Ferrandis et al. 2013).

Data describing the normal Doppler flow velocity parameters of ocular vessels in cats are limited. Therefore, we here aimed at estimating normal blood flow velocity parameters, such as resistive index and pulsatility index through the analysis of the spectral waveforms in normal conscious cats. Sedative and anaesthetic agents can modify systemic and also ocular haemodynamics and subsequently may affect values of ocular impedance indices. Based on this hypothesis, the other aim of our study was to compare, using Doppler ultrasonography, possible changes in the above-mentioned indices in cats after anaesthesia with butorphanol, medetomidine and ketamine.

## MATERIAL AND METHODS

**Animals.** Twelve clinically normal client-owned cats of different breeds (six males, six females) weighing between 2.4 and 4.2 kg and aged between six and 18 months were used. Cats were determined to be healthy based on physical examination, complete haematological and biochemical analysis and complete ophthalmic examination. Animals with signs of ophthalmic, cardiac diseases, or other systemic conditions or symptoms such as neoplasia or fever, receiving NSAID or with a history of systemic diseases, as well as arrhythmia or hypertension were excluded from the study. The ophthalmic examination consisted of slit-lamp biomicroscopy (Kowa SL-15, Kowa, Japan), indirect ophthalmoscopy (Heine Omega 100, Heine Instruments, Germany) and tonometry (TonoVet, Icare, Finland). Animals were classified as grade I according to the classification scale of the American Society of Anaesthesiologists.

To increase the variability of the population, animals of both sexes and of different breeds were used in this study. All measurements were performed before and 15 min after intramuscular administration of anaesthetic drugs.

doi: 10.17221/77/2016-VETMED

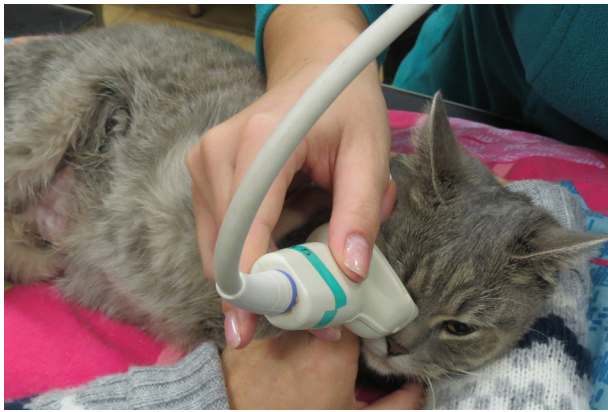

Figure 1. Examination technique in a non-anaesthetised cat. Transducer was positioned in the horizontal plane, with the long axis of the transducer held parallel with the line connecting the medial and lateral canthus. The marker point is pointing nasally

**Examination technique.** Before the non-anaesthetised cats were examined, the animals underwent 15 min of adaptation to the environment in the examination room. Animals were examined with gentle fixation of the head with no pressing on the neck and thorax area (Figure 1). Cats were investigated in left and right lateral recumbency after administration of topical anaesthesia (0.4% oxibuprocaine, Benoxi<sup>®</sup>, Unimed Pharma, Slovakia) and sterile acoustic gel (Sono-Aguagel<sup>®</sup>, Polychem, Slovakia). Images were taken using an Aloka Prosound Alpha 6 ultrasonographic device (Hitachi, Tokyo, Japan) with a 5–13 MHz linear probe. Acoustic gel was applied to the dorsal region and to the zygomatic arch, and the probe was positioned in a horizontal plane. The lateral wall of each eye and the retrobulbar fat were imaged. Both eyes were examined in all cats, with the left eye being examined first. Firstly, conventional ocular ultrasonographic examination in B-mode was used for evaluation of anatomical characteristics of examined eyes. Then, Doppler mode was employed for evaluation of vascular characteristics and for identification of vessels of interest for subsequent spectral Doppler analysis. The long posterior ciliary artery (medial or lateral) was selected, depending on which vessel was most easily visualised or had a better quality of Doppler image (Figure 2). Doppler was performed with a sample volume between 0.5 and 1.0 mm. The main goal was to capture at least three full cardiac cycles displaying as waveform formations.

A standardised imaging protocol was used and machine settings (with low to medium Doppler flow settings), examination room, observer and

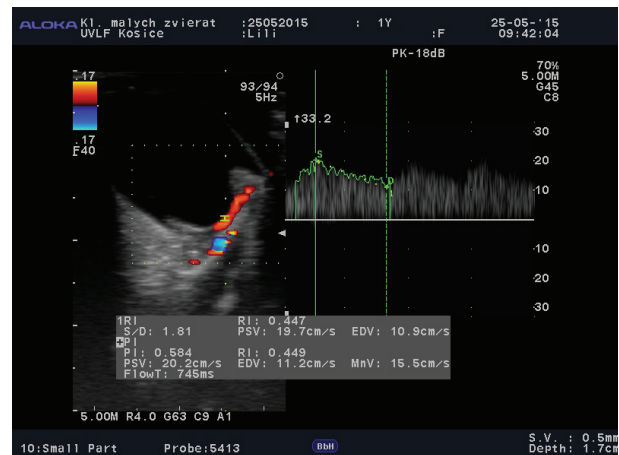


Figure 2. Colour Doppler visualisation of ocular vasculature and pulsed Doppler volume sample location in the ciliary artery in an anaesthetised cat

person responsible for fixation of cats were kept constant to minimise technical errors. The impedance indices were calculated using ultrasound machine software, after manually entering peak systolic velocity, end diastolic velocity, and time average maximum velocity. All examinations together with waveform analyses were performed by the same observer.

**Anaesthesia protocol.** Selection of anaesthesia was made based on the frequency of its use in our institution. A combination of butorphanol, medetomidine and ketamine was used in lower doses (0.2 mg/kg of butorphanol and 60 µg/kg of medetomidine and 3 mg/kg of ketamine). Anaesthesia was administered intramuscularly, mixed together in one syringe. Following injection, the cats were kept in a quiet, dark room, under the direct supervision of the anaesthesiologist. Animals were examined 15 min after application of the injection, regardless of the animal's anaesthesia level. All measurements described above were repeated in the anaesthetised cats. Owner consent was obtained before ultrasonography and anaesthesia.

**Statistical analysis.** Obtained data were processed and evaluated using GraphPad Prism version 6.1 for Windows, GraphPad Software, San Diego, USA, www.graphpad.com. All the measurements were performed three times to minimise technical errors.

To obtain a range of values for clinically normal non-anaesthetised and anaesthetised cats, 95% confidence intervals were calculated for RI and PI. Values were compared between left and right eyes by use of paired Student's *t*-tests, whereas values

were compared between genders by use of unpaired Student's *t*-tests. The paired Student's *t*-test was used for comparison of velocity indices before and after anaesthesia. Relationships between body weight, RI and PI before and after anaesthesia were assessed by use of correlation matrices. Differences were considered significant when  $P < 0.05$ .

## RESULTS

Results of obtained RI and PI are summarised in Table 1. No statistically significant differences were noted between the mean values of RI and PI for the right vs the left eye or male vs female cats ( $P > 0.05$ ). No differences were found between the right and left ocular velocity indices; therefore, mean values were obtained, which incorporated both right and left eye measurements. The mean values  $\pm$  SD of ocular RI and PI in non-anaesthetised cats were  $0.55 \pm 0.07$  and  $0.78 \pm 0.08$ , respectively, and were significantly higher than RI and PI in anaesthetised cats  $0.39 \pm 0.08$  and  $0.50 \pm 0.1$ , respectively,  $P < 0.0001$ .

Moreover, no significant correlation was found between body weight and RI ( $r = 0.338$ ;  $P = 0.282$ ) or PI ( $r = 0.564$ ;  $P = 0.056$ ), respectively.

## DISCUSSION

Normal values for the ocular RI and PI before anaesthesia were similar to those reported in a previous study in healthy non-anaesthetised cats (Novellas et al. 2007a).

Lee et al. (2002), Sindak et al. (2003) and Novellas et al. (2007b) reported that there were no significant differences in the RI values between the left and right eyes, or between male and female dogs of different breeds. The results of this present study support the findings of these authors, because we

similarly did not find any significant differences in RI between left and right eyes or between male and female cats. Further, we also did not find any significant differences in PI between left and right eyes, or between male and female cats.

External pressure from the transducer may increase intraocular pressure during the examination, and this will affect subsequent measurements of blood flow velocity, i.e. RI and PI. To minimise external pressure on the eye in the present study, images were obtained by a lateral approach through the lateral orbital ligament in a technique modelled on Lee et al. (2002).

No previous studies deal with the optimal examination position for animals. In this study, left and right lateral recumbency was used, which is, in our opinion, acceptable for cats, and does not result in significant external pressure on the animal's neck or thorax.

To minimise the variability of the results, the examinations were performed by the same sonographer, with the stable fixation technique performed by one person, in the same examination room, after 15 min of adaptation to the environment and using a standardised examination protocol. In all cats, both eyes were examined (left eye first).

Gelatt-Nicholson et al. (1999a) visualised and identified a majority of the orbital and ocular blood vessels. In that study, the long posterior ciliary arteries (LPCA) were evaluated as easily identifiable, with very good quality of Doppler images (Gelatt-Nicholson et al. 1999a). Novellas et al. (2007a) also reported the LPCA to be the most reliably recognisable arteries of the eye, visualised at either the three or nine o'clock position within the sclera.

Anaesthetic agents can alter systemic and ocular haemodynamics and subsequently affect vascular resistance indices. The effects of certain sedative protocols on Doppler variables of different canine ocular arteries has already been character-

Table 1. Measurements of impedance indices for the long posterior ciliary artery in 12 cats (24 eyes)

	Left eye		Right eye		<i>P</i> -value	Both eyes	
	mean $\pm$ SD	95% CI	mean $\pm$ SD	95% CI		mean $\pm$ SD	95% CI
<b>Non-anaesthetised cats</b> ( $n = 24$ )							
Resistive index	$0.55 \pm 0.07$	0.51–0.59	$0.55 \pm 0.06$	0.51–0.59	0.974	$0.55 \pm 0.07$	0.52–0.58
Pulsatility index	$0.78 \pm 0.07$	0.74–0.82	$0.76 \pm 0.08$	0.71–0.81	0.331	$0.77 \pm 0.07$	0.74–0.80
<b>Anaesthetised cats</b> ( $n = 24$ )							
Resistive index	$0.40 \pm 0.07$	0.35–0.45	$0.38 \pm 0.09$	0.32–0.43	0.356	$0.39 \pm 0.08$	0.36–0.42
Pulsatility index	$0.52 \pm 0.10$	0.45–0.58	$0.49 \pm 0.11$	0.42–0.56	0.350	$0.50 \pm 0.10$	0.46–0.54

doi: 10.17221/77/2016-VETMED

ised (Gelatt-Nicholson et al. 1999a; Novellas et al. 2007b). Intramuscular administration of midazolam and butorphanol increases ocular blood flow resistance (Novellas et al. 2007a).

The anaesthetic combination used in the present study consisted of butorphanol, medetomidine and ketamine (0.2 mg/kg of butorphanol, 60 µg/kg of medetomidine and 3 mg/kg of ketamine in one syringe intramuscularly). The used anaesthetics significantly decreased ocular RI and PI. This combination is routinely used to anaesthetise cats that are difficult to restrain and provides for rapid and predictable anaesthetic duration and effect. It is appropriate for uncooperative, unmanageable, excited and/or fractious animals.

In summary, in this study we have described the effects of intramuscular anaesthesia with butorphanol, medetomidine and ketamine on RI and PI of the long posterior ciliary artery in healthy cats. Values of the impedance indices of anaesthetised cats were statistically significantly lower than values of non-anaesthetised, healthy cats,  $P < 0.0001$ . Our results support the hypothesis that the use of anaesthetics causes changes in ocular haemodynamics in cats.

In addition, our investigations further underline the suitability of colour Doppler imaging as a method for examination of retrobulbar blood flow dynamics in feline clinical practice and research. Moreover, the differential determination of retrobulbar blood velocities might lead to a better understanding of the pathophysiology of ocular diseases with disturbed ocular haemodynamics.

In conclusion, the reported RI and PI values of healthy non-anaesthetised cats and cats under anaesthesia can be applied as a baseline for further study of ocular blood flow velocities in vascular diseases. The obtained values are especially useful in cases, where, due to poor cooperation of the cat, restraint is needed and values must be interpreted with regard to the haemodynamic changes occurring during anaesthesia.

## REFERENCES

- Choi H, Lee Y, Yeon S, Lee H, Lee H (2011): Effects of anti-glaucoma drugs on resistive index of the medial long posterior ciliary artery using color Doppler imaging in Beagle dogs. *Journal of Veterinary Science* 12, 99–101.
- Ferrandis I, Jakovljevic S, Aprea F, Corletto F (2013): Effect of two sedative protocols and hepatosplenic disease on Doppler indices of splenic arteries in dogs: A preliminary study. *Veterinary Journal* 197, 713–716.
- Gelatt-Nicholson KJ, Gelatt KN, MacKay E, Brooks DE, Newell SM (1999a): Doppler imaging of the ophthalmic vasculature of the normal dog: blood velocity measurements and reproducibility. *Veterinary Ophthalmology* 2, 87–96.
- Gelatt-Nicholson KJ, Gelatt KN, MacKay E, Brooks DE, Newell SM (1999b): Comparative Doppler imaging of the ophthalmic vasculature in normal Beagles and Beagles with inherited primary open-angle glaucoma. *Veterinary Ophthalmology* 2, 97–105.
- Goncalves GF, Pippi NL, Leme MC, Custodio AT, da Silva AV, Romagnoli P, Pachaly JR, Bottin JMP, Livero FA (2008): Correlation between arterial pressure and blood flow in the external ophthalmic artery in cats (*Felis catus* Linnaeus, 1758). *Brazilian Journal of Veterinary Research and Animal Science* 45, 57–66.
- Gonzalez EM, Rodriguez A, Garcia I (2001): Review of ocular ultrasonography. *Veterinary Radiology and Ultrasound* 42, 485–495.
- Lee H, Chang D, Lee Y, Eom K, Choi H, Seo K, Choi M, Yoon J (2002): Use of color Doppler imaging for determining the resistive index of the medial long posterior ciliary artery in clinically normal conscious dogs. *American Journal of Veterinary Research* 63, 211–214.
- Lee K, Choi M, Yoon J, Jung J (2004): Spectral waveform analysis of major arteries in conscious dogs by Doppler ultrasonography. *Veterinary Radiology and Ultrasound* 45, 166–171.
- Legarthy J, Thorup E (1989): Characteristics of Doppler blood-velocity waveforms in a cardiovascular in vitro model. II. The influence of peripheral resistance, perfusion pressure, and blood flow. *Scandinavian Journal of Clinical and Laboratory Investigation* 49, 459–464.
- Liu CJ, Chou Y, Chou JC, Chiou HJ, Chiang SC, Liu JH (1997): Retrobulbar haemodynamic changes studied by colour Doppler imaging in glaucoma. *Eye* 11, 818–826.
- Macri F, Pugliese M, Di Petro S, Coco MA, Liotta L, Niutta PP, Nardi S, Quartuccio M, Lanteri G, Piccionello AP (2015): Doppler ultrasonographic estimation of renal resistive index in horse: Comparison between left and right kidneys. *Journal of Equine Veterinary Science* 35, 111–115.
- Nassr MA, Morris CL, Netland PA, Karcioğlu ZA (2009): Intraocular pressure change in orbital disease. *Survey of Ophthalmology* 54, 519–544.
- Novellas R, Espada Y, Ruiz de Gopegui R (2007a): Doppler ultrasonographic estimation of renal and ocular resistive

- and pulsatility indices in normal dogs and cats. *Veterinary Radiology and Ultrasound* 48, 69–73.
- Novellas R, Ruiz de Gopegui R, Espada Y (2007b): Effect of sedation with midazolam and butorphanol on resistive and pulsatility indices in healthy dogs. *Veterinary Radiology and Ultrasound* 48, 276–280.
- Ostrowska J, Kielbowicz Z, Zaleska-Dorobisz U, Atamaniuk W, Pietsch-Fulbiszevska A, Kinda W (2016): Resistive index (RI) obtained in renal interlobar arteries of normal dogs and cats by means of Doppler ultrasonography. *Pakistan Veterinary Journal* 36, 45–48.
- Pozniak MA, Kelcz F, Stratta RJ, Oberley TD (1988): Extraneous factors affecting resistive index. *Investigative Radiology* 23, 899–904.
- Sindak N, Ozturk A, Biricik HS (2003): Color Doppler Imaging of the internal ophthalmic and long posterior ciliary arteries in the dog. *Turkish Journal of Veterinary and Animal Sciences* 27, 1219–1224.
- Szatmari V, Sotonyi P, Voros K (2001): Normal duplex Doppler waveform of major abdominal blood vessels in dogs: A review. *Veterinary Radiology and Ultrasound* 42, 93–107.

Received: May 9, 2016

Accepted after corrections: October 29, 2016