

Corpus luteal angiogenesis in a high milk production dairy breed differs from that of cattle with lower milk production levels

S. KAESSMEYER¹, H. HUENIGEN¹, S. AL MASRI¹, P. DIECKHOEFER¹,
K. RICHARDSON², J. PLENDL¹

¹Department of Veterinary Medicine, Institute for Veterinary Anatomy, Freie Universitat Berlin, Berlin, Germany

²College of Veterinary Medicine, Murdoch University, Murdoch, Australia

ABSTRACT: Globally, high producing, young dairy cows often have health and fertility problems such as ovarian, uterine and placental dysfunction, mastitis and impaired wound healing. These health issues can result in a shortened average lifespan of fewer than three lactations. We hypothesise that many of these health issues may be an effect of altered angiogenesis. Hence, the aim of this pilot study was to investigate the status of vascularisation in the corpus luteum of a high milk-producing cattle breed (Holstein Friesian) compared with that of low milk producing beef cattle (Limousin) and of dual purpose cattle (Fleckvieh, Rotbunt). The corpus luteum was chosen because as a transient endocrine gland it is one of the few tissues with physiological angiogenesis in the adult. Blood vessels were labelled in paraffin sections of corpora lutea with the lectin *Bandeiraea simplicifolia* agglutinin I and the following angiogenesis parameters were analysed morphometrically using image analysis: (a) number of blood capillaries per mm², (b) intercapillary distance, (c) percentage area occupied by blood vessels and (d) area of blood vessel lumina (µm²). This analysis revealed that the extent of corpus luteal vascularisation is greater in high milk-producing cattle than in beef and dual purpose cattle as shown by a significantly higher number of blood capillaries per mm², significantly shorter intercapillary distances and a higher percentage of the corpus luteum area covered by blood vessels (non-significant). Only the average value of the luminal area of the luteal blood capillaries in the high milk-producing cattle is smaller than that measured in the low producing cattle.

Keywords: Holstein Friesian; dairy cows; dual purpose cows; corpus luteum; vascularisation; capillary; angiogenesis

In recent years, there has been a significant increase in milk production in all milk-producing countries worldwide due to the increased milk yields of high producing dairy cows (HPC), particularly of the dominant milk-producing breed Holstein Friesian (Boichard and Brochard 2012). Concurrent with this there has been a high frequency of complex health issues occurring in young Holstein Friesian cows. This is a major problem especially when one considers that the average lifespan of HPC is fewer than three lactations (Martens 2015).

HPC often suffer from health and fertility problems at a younger age than other cattle breeds, in which these typically occur at a later stage of life (Freyer et al. 2008; Sorensen et al. 2008). These

observations might be due to feeding, management or individual differences. However, there appears to be a genetic relationship between the occurrence of specific diseases and high milk yields in Holstein Friesian cows (Pritchard et al. 2013).

The most significant health issues of HPC are clinical mastitis, cystic ovaries, and lameness (Koeck et al. 2014). Additional health issues include uterine and placental dysfunction, hepatopathy and impaired wound healing (Barbaro et al. 2016; Bernadotte et al. 2016). These diseases as well as impaired wound healing, frequently result in the premature loss of these animals from the dairy industry. This in turn has animal welfare implications because animals suffering from the early onset of

disease often have to be culled from the herd at a young age. Overall there is a major economic downside associated with the treatment of diseases and the replacement of cows. Consequently, research aimed at solving the health problems in these HPC herds is of great medical and economic importance (Egger-Danner et al. 2015).

Disruptions to the normal dynamics of vascular repair such as inadequate proliferation, reparation and regeneration of blood capillaries may underlie some of the health problems of HPC. Apart from exceptions such as hair follicle growth, physiological blood vessel development in adult animals can be found only in females, e.g., in the uterus and ovaries as part of their reproductive cycle, particularly during the development of the corpus luteum and during the development of the mammary gland and placenta in pregnant female animals. All other forms of neovascularisation in adult animals only occur as part of regenerative processes such as wound healing or pathological processes like tumour growth (Kaessmeyer and Plendl 2009).

The main mechanisms underlying blood vessel development are vasculogenesis and angiogenesis. Whereas angiogenesis describes the formation of capillaries from pre-existing blood vessels by migration, proliferation and three-dimensional arrangement of endothelial cells, vasculogenesis denotes the *de novo* formation of blood vessels by differentiation of endothelial stem and progenitor cells (Carmeliet 2005). According to recent findings, vascular stem cells are found not only in prenatal animals but also in organs of adult animals, especially in the wall of blood vessels (Ergun et al. 2011).

Our group has identified adult endothelial stem cells in the ovaries and particularly in the corpora lutea of dairy cows predominantly situated within the tunica media of arterial vessel walls (Schoen et al. 2012).

Encouraged by the recent findings of Aragona et al. (2016) who reported that there is a close connection between the regeneration ability and the capabilities of endothelial progenitor cells, we hypothesise that many health issues of high producing Holstein Friesian cows are an effect of altered angiogenesis or vasculogenesis. Consequently the objective of this pilot study was to investigate blood vessel development in the corpus luteum of HPC (specifically high milk-producing Holstein Friesian dairy cows) and to compare this with that of beef and dual purpose cattle (non high-producing breeds [NHPC]).

MATERIAL AND METHODS

Corpora lutea from non-pregnant healthy cows were collected within 10 min of slaughter from six Holstein Friesian dairy cows (HPC) and from five NHPC cattle (Limousin ($n = 1$), Rotbunt ($n = 1$), and Fleckvieh ($n = 3$)) aged between 27 and 113 months, from a local slaughterhouse. One ovary was cut in half at the point of the greatest diameter of the corpus luteum (Cl). Cl were then dissected from the ovarian stroma, cut into 1 cm³ pieces and fixed in 10% neutral buffered formalin. The specimens were dehydrated using a series of ascending concentrations of ethanol solutions and processed for embedding in paraffin wax according to standard procedures. To prepare corpora lutea for histological staining, 6- μ m-thick serial transverse sections were cut. These were dewaxed using xylene, rehydrated through descending concentrations of ethanol and stained with haematoxylin and eosin, as well as using the Ladewig technique according to standard procedures (Bock 1989). The luteal stage was then confirmed by microscopic examination of the H&E-stained sections.

***Bandeiraea simplicifolia* agglutinin I lectin histochemistry.** Endothelial cells of capillaries were identified using *Bandeiraea simplicifolia* agglutinin I (BSL1) labelling, as described by Plendl et al. (1996). The sections were dewaxed using xylene, rehydrated using descending concentrations of ethanol and washed in distilled water. To inhibit endogenous peroxidase activity, sections were incubated with 3% H₂O₂ in methanol for 15 min. In order to reduce non-specific lectin binding, sections were incubated in 1% normal bovine serum (Sigma-Aldrich, Taufkirchen, Germany) in phosphate-buffered saline (PBS, Sigma, Taufkirchen, Germany). Incubation with 10 μ g/ml biotinylated BSL1 (Vector, Burlingame, USA) was subsequently carried out overnight in a humidity chamber at 4 °C, whereupon the sections were incubated with StreptABC complex (Dako, Hamburg, Germany) and prepared for 45 min according to the manufacturer's instructions. Visualisation of labelling was accomplished using diaminobenzidine (DAB) solution (Dako, Hamburg, Germany) for 45 s. DAB solution was prepared by dissolving 10 mg DAB (tablet) in 50 ml PBS with 25 μ l 30% H₂O₂. The sections were counterstained with Mayer's haematoxylin, then dehydrated through ascending concentrations of ethanol, cleared in xylene and mounted in Canada balsam (Roth, Karlsruhe,

doi: 10.17221/72/2016-VETMED

Germany). All dilutions and thorough washes between steps were performed using PBS. All steps were performed at room temperature. As a control, sections selected at random from the series were incubated using BSL1 solution in the presence of 200mM galactose/200mM *N*-acetyl-galactosamine (Sigma, Taufkirchen, Germany) to detect evidence of competitive inhibition.

Morphometric analysis of luteal blood capillaries. In each cross-section of the corpus luteum, the areas of interest were defined by randomly choosing 10 visual fields under 400 × magnification. The total area analysed of each corpus luteum was 185.176 μm². To determine the density and the area of the luteal blood capillaries, the following parameters in BSL 1-labelled vasculature were measured using the image analysis system LUCIA 4.0 (Nikon, Duesseldorf, Germany) linked to a SONY DXC 930 P camera (Sony, Munchen, Germany): number of blood capillaries per mm², intercapillary distance, percentage area occupied by blood vessels, area of blood vessel lumina (in μm²).

Statistical analysis. The corpora lutea of HPC were compared to the corpora lutea of NHPC cows. Statistical analyses were performed using SPSS for Windows v. 20 software (SPSS, Chicago, IL). The mean values of the collected parameters, irrespective of corpus luteum phase, were compared between both groups (HPC vs NHPC) using the Mann-Whitney *U*-test. *P* < 0.05 was considered statistically significant. Results were presented as Box-and-whisker plots (median, interquartile range, and range).

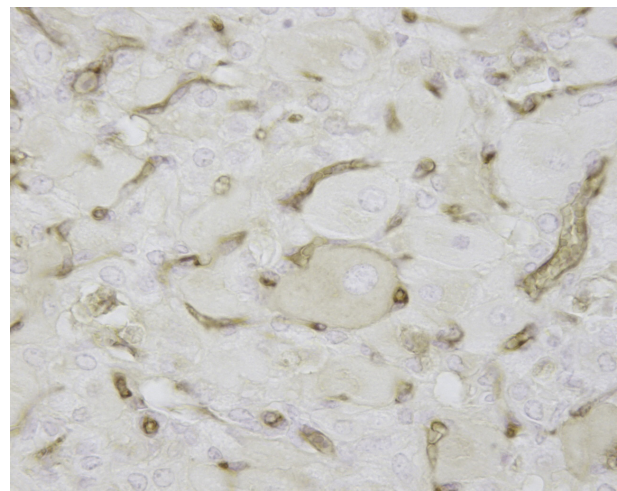


Figure 1. *Bandeiraea simplicifolia* I lectin-labelling (brown) of endothelial cells of capillaries of a mature corpus luteum in a Holstein Friesian cow (light microscopy, sections counterstained with Mayer's haematoxylin, × 400 magnification)

RESULTS

The labelling of the capillaries of endothelial cells was verified using *Bandeiraea simplicifolia* agglutinin I (Figure 1).

The area of luteal blood capillaries

The area covered by luteal blood capillaries was larger in the HPC than in the NHPC (Figure 2). The average area of corpora lutea covered by blood

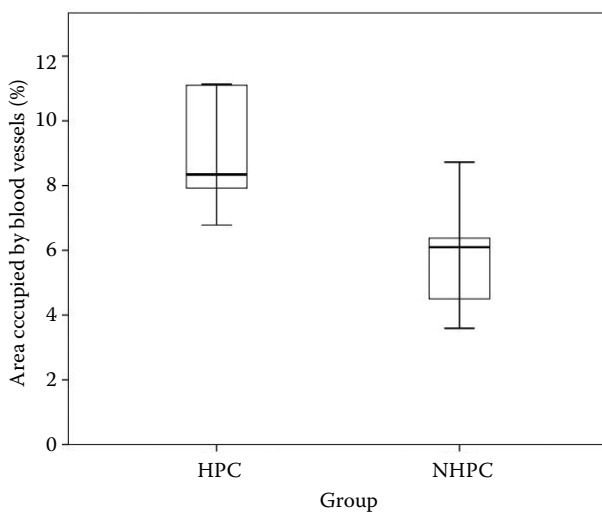


Figure 2. Average area covered by luteal blood capillaries as a percentage per cross-section of corpora lutea from HPC and NHPC cows

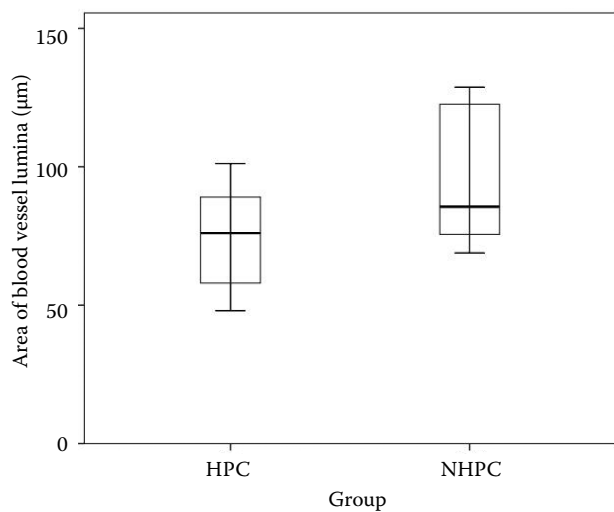


Figure 3. Average of the luminal area of luteal blood capillaries in the corpus luteum of HPC and NHPC cows

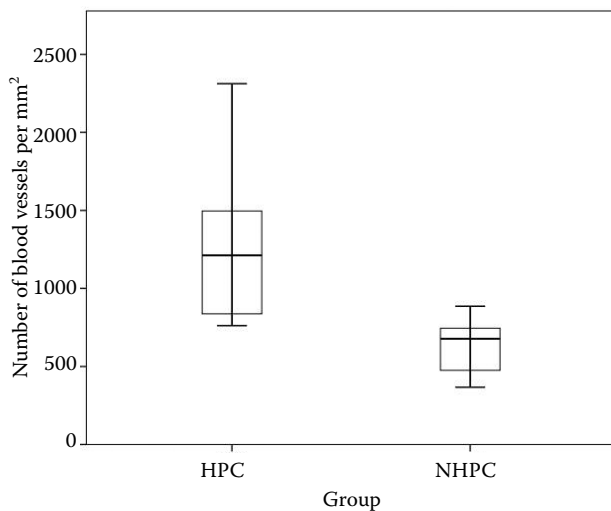


Figure 4. Average number of capillaries per mm² of luteal tissue in HPC and NHPC cows

capillaries was 8.93% in the HPC and 5.85% in the NHPC. However, this difference was statistically not significant ($P = 0.052$). The average value of the luminal area of the luteal blood capillaries in the HPC was smaller than that measured in the NHPC (74.71 and 96.25 μm^2 , respectively; Figure 3). This difference was not significant ($P = 0.329$).

Density of the luteal blood capillaries

The number of luteal blood capillaries per mm² showed a significant difference between the groups ($P = 0.017$). The HPC animals have an average of 1305.05 blood capillaries in each mm² of the corpus luteum, whereas the NHPC animals had about half the number of capillaries in each mm² (630.16; Figure 4).

Similarly, the intercapillary distance of the corpora lutea showed a significant difference between the groups ($P = 0.009$). The mean intercapillary distance was smaller in the HPC (20.27 μm) than in the NHPC (32.55 μm ; Figure 5).

Details of the density and the area of the luteal blood capillaries are reported in Table 1.

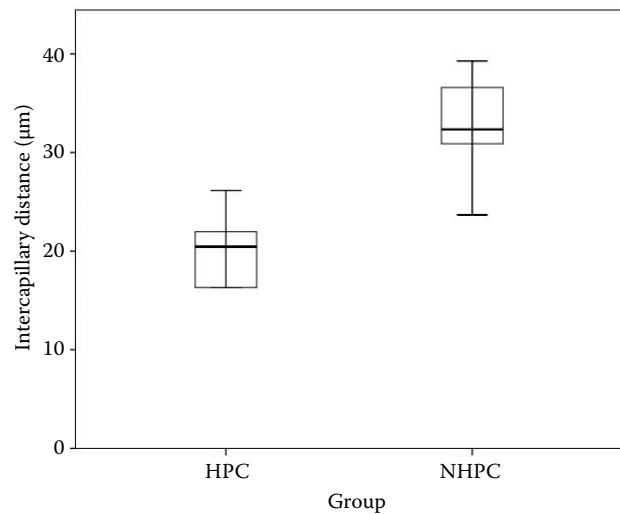


Figure 5. Average intercapillary distance of the corpora lutea from HPC and NHPC cows

DISCUSSION

The aim of this pilot study was to investigate the status of vascularisation in the corpora lutea of HPC compared with that of NHPC breeds. Our results reveal that there is greater corpus luteal vascularisation in HPC than in NHPC as shown by a significantly higher number of blood capillaries per mm² and significantly shorter intercapillary distances. The overall blood vascular volumes within the corpora lutea of HPC, as indicated by a higher percentage of the Cl area covered by blood vessels, was significantly higher when compared to that of the NHPC.

Vascularisation is a general requirement for growth; be it physiological as found in the female genital tract during the oestrous cycle and in pregnancy, pathophysiological such as in wound healing, or pathological as found in tumours (Carmeliet 2005). In warm blooded animals any tissue exceeding a diameter of 1 mm cannot be supplied by diffusion alone, but requires a capillary bed of its own (Folkman 1990). The Cl, a transient endocrine gland, is one of the most highly vascularised tissues in the body (Plendl 2000). Vascularisation in

Table 1. Detailed information of the assessed density and area of the blood capillaries and mean \pm SD of the measured parameters in the corpora lutea of HPC and LPC cows

Number of animals	6 HPC	5 NHPC
Number of blood capillaries per mm ²	1305.05 \pm 570.63	630.16 \pm 208.50
Intercapillary distance in μm	20.27 \pm 3.73	32.55 \pm 5.98
Percentage area occupied by blood vessels	8.93 \pm 1.78	5.85 \pm 1.96
Area of blood vessel lumina μm^2	74.70 \pm 19.52	96.25 \pm 27.57

doi: 10.17221/72/2016-VETMED

the corpus luteum begins immediately after ovulation and accompanies and sustains its development. Vascular processes in the CI are strictly controlled and blood vessels regress completely within a short period of time. Due to the rapid development, remodelling and regression of its vascularisation the CI is an excellent model of blood vessel development in the adult animal (Amselgruber et al. 1999; Davis et al. 2003).

The dense vascularisation in the CI of HPC compared to NHPC may be due to an imbalance between the regulators of angiogenesis, i.e., between pro- and anti-angiogenic factors (Miyamoto et al. 2010) resulting in either activation of angiogenesis and/or vasculogenesis, respectively, or defective anti-angiogenesis.

Physiological angiogenesis is regulated by a delicate balance of pro- and anti-angiogenic stimulants (Rao et al. 2015). The most important proangiogenic factor is VEGF (Ferrara et al. 2003). Blood vessels in the bovine CI are under the control of VEGF, its receptors and its inhibitors, as shown by Hunigen et al. (2008) who investigated vascular dynamics during the development and regression of the bovine CI. These authors immunolocalised vascular endothelial growth factor A, vascular endothelial growth factor receptor 2, and angiopoietin 2 in different luteal cell types. Regression of the CI is associated with anti-angiogenesis, i.e. the opposite of angiogenesis, orchestrated by the upregulation of prostaglandins, transforming growth factor beta 1, and additionally by the downregulation of the proangiogenic factors (Maroni and Davis 2011).

Angiogenesis is initiated by tissue demands for oxygen and nutrients, resulting in a hypoxia/re-oxygenation cycle that in turn promotes the formation of reactive oxygen species (ROS) (Kim and Byzova 2014). One of the most important functions of ROS is the promotion of angiogenesis via the VEGF signalling pathway (Kim and Byzova 2014). Of necessity, HPC undergo massive metabolic adaptations at the onset of lactation, and it has been postulated that some of these physiological events may negatively impact the health of dairy cows (Sordillo et al. 2009; Sharma et al. 2011). Evaluation of the metabolic status of HPC showed an increased production of reactive oxygen species and reduced availability of antioxidant defences, resulting in increased oxidative stress (Sharma et al. 2011) during pregnancy and lactation.

Apart from angiogenesis, another reason for the increased vascularisation of the CI of HPC could

be the stimulation of vasculogenesis, i.e., the development of blood vessels from vascular stem and progenitor cells (Asahara and Kawamoto 2004). Our group has identified adult endothelial stem cells in the ovaries and particularly in the corpora lutea of dairy cows *in vitro* and *in situ*. *In vitro*, endothelial cells isolated from the CI showed intense proliferation, built typical cellular clusters reminiscent of *de novo* vasculogenesis and organised into capillary-like tubes with an internal lumen as seen by electron microscopy (Kaessmeyer and Plendl 2009). In *in situ* specimens of bovine ovaries, endothelial stem cells were found to be predominantly within the tunica media of arterial vessel walls (Schoen et al. 2012). At this point, we can only speculate whether increased vascularisation in HPC is restricted to the CI or whether it affects the vascular system of other organs or even the animal as a whole.

In the light of the many health problems of HPC the following considerations may be interesting. Generally Jersey cattle are long-lived and normally produce an average of 13 l of milk a day. This contrasts dramatically with the milk yield of today's Friesian breeds that can reach about 33 l of milk a day (Dobson et al. 2007), making them comparable to high-performance human athletes.

High performance training in athletes has been found to induce angiogenesis, because vigorous exercise causes oxidative stress that in turn results in an increase in total VEGF mRNA (Jensen et al. 2004). Moreover, many high-performance athletes that are subject to intense training regimens are known to suffer from premature ageing (Wright 2012) including health problems associated with accelerated senescence (Kurz et al. 2004). For example, Rae et al. (2010) measured the DNA telomere length of skeletal muscle in experienced endurance runners and found that there is an inverse relationship between exposure to endurance exercise and minimum telomere length, and by implication, the proliferative potential of skeletal muscle satellite cells (stem cells). They concluded that endurance running influenced the proliferative potential of stem cells negatively. Recent studies (Alt et al. 2012; Jung and Brack 2014) showed that ageing entails an impaired function of the somatic stem cells that partly corresponds to an exhaustion of stem cells and their resources. This affects the stem cell pool of various cell populations, such as haemopoietic cells, which are precursors of vascular endothelial cells (Alt et al. 2012).

It is well known that HPC often succumb to poor health even relatively early in life. HPC are considerably more prone to disease and their tissue regeneration appears to be low. Their health issues frequently manifest as impaired wound healing and infertility, the main reasons leading to their premature slaughter by the time they are five years old. In contrast, cattle over the course of the nineteenth century and up until the mid-1960s had lifespans generally reaching the mid-teens to late-teens and even above 20 years (Jones and Sadler 2012). Premature senescence after a short lifespan characterised by constant, maximum performance taking its toll on their bodies seems to be the fate of HPC. Metabolic reserves and the regenerative capacity of Holstein Friesian at a young age seem to be exhausted, suggesting that their stem cell pool is depleted. The precise molecular mechanisms of the age-related decline in the function of (endothelial) stem and progenitor cells are still unclear and require further investigation.

CONCLUSIONS

Higher numbers of blood capillaries per mm² and a higher percentage of the corpus luteum area covered by blood vessels indicate either activated angiogenesis or defective anti-angiogenesis, probably resulting in the early exhaustion of the regenerative capacity of high milk-producing cattle. Further studies are underway to determine whether this is a local ovarian or systemic phenomenon.

Acknowledgements

The authors thank Ilona Kuster-Krehahn for technical assistance and Wiebke Gentner for efficient language editing.

REFERENCES

- Alt EU, Senst C, Murthy SN, Slakey DP, Dupin CL, Chaffin AE, Kadowitz PJ, Izadpanah R (2012): Aging alters tissue resident mesenchymal stem cell properties. *Stem Cell Research* 8, 215–225.
- Amselgruber WM, Schafer M, Sinowatz F (1999): Angiogenesis in the bovine corpus luteum: An immunocytochemical and ultrastructural study. *Anatomia Histologia Embryologia* 28, 157–166.
- Aragona CO, Imbalzano E, Mamone F, Cairo V, Lo Gullo A, D'ascola A, Sardo MA, Scuruchi M, Basile G, Saitta A, Mandraffino G (2016): Endothelial progenitor cells for diagnosis and prognosis in cardiovascular disease. *Stem Cells International*. Advance online publication, DOI: <http://dx.doi.org/10.1155/2016/8043792>.
- Asahara T, Kawamoto A (2004): Endothelial progenitor cells for postnatal vasculogenesis. *American Journal of Physiology Cell Physiology* 287, C572–C579.
- Barbaro PM, Ziegler DS, Reddel RR (2016): The wide-ranging clinical implications of the short telomere syndromes. *Internal Medicine Journal* 46, 393–403.
- Bernadotte A, Mikhelson VM, Spivak IM (2016): Markers of cellular senescence. Telomere shortening as a marker of cellular senescence. *Aging (Albany NY)* 8, 3–11.
- Bock P (ed.) (1989): *Romeis Mikroskopische Technik*. 17th edn. Urban und Schwarzenberg, Munchen. 179–249.
- Boichard D, Brochard M (2012): New phenotypes for new breeding goals in dairy cattle. *Animal* 6, 544–550.
- Carmeliet P (2005): Angiogenesis in life, disease and medicine. *Nature* 438, 932–936.
- Davis JS, Rueda BR, Spanel-Borowski K (2003): Microvascular endothelial cells of the corpus luteum. *Reproductive Biology and Endocrinology* 1, 89.
- Dobson H, Smith R, Royal M, Knight C, Sheldon I (2007): The high-producing dairy cow and its reproductive performance. *Reproduction in Domestic Animals* 42, 17–23.
- Egger-Danner C, Cole JB, Pryce JE, Gengler N, Heringstad B, Bradley A, Stock KF (2015): Invited review: Overview of new traits and phenotyping strategies in dairy cattle with a focus on functional traits. *Animal* 9, 191–207.
- Ergun S, Tilki D, Klein D (2011): Vascular wall as a reservoir for different types of stem and progenitor cells. *Antioxidants and Redox Signaling* 15, 981–995.
- Ferrara N, Gerber HP, Lecouter J (2003): The biology of VEGF and its receptors. *Nature Medicine* 9, 669–676.
- Folkman J (1990): What is the evidence that tumors are angiogenesis dependent? *Journal of The National Cancer Institute* 82, 4–6.
- Freyer G, Konig S, Fischer B, Bergfeld U, Cassell BG (2008): Invited review: Crossbreeding in dairy cattle from a German perspective of the past and today. *Journal of Dairy Science* 91, 3725–3743.
- Hunigen H, Bisplinghoff P, Plendl J, Bahramsoltani M (2008): Vascular dynamics in relation to immunolocalisation of VEGF-a, VEGFR-2 and Ang-2 in the bovine corpus luteum. *Acta Histochemica* 110, 462–472.
- Jensen L, Bangsbo J, Hellsten Y (2004): Effect of high intensity training on capillarization and presence of angiogenic factors in human skeletal muscle. *Journal of Physiology* 557, 571–582.

doi: 10.17221/72/2016-VETMED

- Jones GG, Sadler P (2012): A review of published sources for age at death in cattle. *Environmental Archaeology* 17, 1–10.
- Jung Y, Brack AS (2014): Cellular mechanisms of somatic stem cell aging. *Current Topics in Developmental Biology* 107, 405–438.
- Kaessmeyer S, Plendl J (2009): Angiogenesis and vasculogenesis in the corpus luteum in vitro. *Clinical Hemorheology and Microcirculation* 41, 83–101.
- Kim YW, Byzova TV (2014): Oxidative stress in angiogenesis and vascular disease. *Blood* 123, 625–631.
- Koeck A, Loker S, Miglior F, Kelton DF, Jamrozik J, Schenkel FS (2014): Genetic relationships of clinical mastitis, cystic ovaries, and lameness with milk yield and somatic cell score in first-lactation Canadian Holsteins. *Journal of Dairy Science* 97, 5806–5813.
- Maroni D, Davis JS (2011): Tgfb1 disrupts the angiogenic potential of microvascular endothelial cells of the corpus luteum. *Journal of Cell Science* 124, 2501–2510.
- Martens H (2015): Metabolic load and health risks of dairy cows in early lactation (in German). *Tieraerztliche Umschau* 70, 496–504.
- Miyamoto A, Shirasuna K, Shimizu T, Bollwein H, Schams D (2010): Regulation of corpus luteum development and maintenance: Specific roles of angiogenesis and action of prostaglandin f2alpha. *Society of Reproduction and Fertility Supplement* 67, 289–304.
- Plendl J (2000): Angiogenesis and vascular regression in the ovary. *Anatomia Histologia Embryologia* 29, 257–266.
- Plendl J, Neumuller C, Sinowatz F (1996): Differences of microvascular endothelium in the bovine corpus luteum of pregnancy and the corpus luteum of the estrous cycle. *Biology of the Cell* 87, 179–188.
- Pritchard T, Coffey M, Mrode R, Wall E (2013): Genetic parameters for production, health, fertility and longevity traits in dairy cows. *Animal* 7, 34–46.
- Rae DE, Vignaud A, Butler-Browne GS, Thornell LE, Sinclair-Smith C, Derman EW, Lambert MI, Collins M (2010): Skeletal muscle telomere length in healthy, experienced, endurance runners. *European Journal of Applied Physiology* 109, 323–330.
- Rao N, Lee YF, Ge R (2015): Novel endogenous angiogenesis inhibitors and their therapeutic potential. *Acta Pharmacologica Sinica* 36, 1177–1190.
- Schoen K, Hirschberg RM, Plendl J, Kaessmeyer S (2012): Identification of CD133-, CD34- and KDR-positive cells in the bovine ovary: A new site of vascular wall resident endothelial progenitor cells. *Clinical Hemorheology and Microcirculation* 52, 67–84.
- Sharma LK, Fang HZ, Liu JT, Vartak R, Deng JN, Bai YD (2011): Mitochondrial respiratory complex I dysfunction promotes tumorigenesis through ROS alteration and AKT activation. *Human Molecular Genetics* 20, 4605–4616.
- Sordillo LM, Contreras GA, Aitken SL (2009): Metabolic factors affecting the inflammatory response of periparturient dairy cows. *Animal Health Research Reviews* 10, 53–63.
- Sorensen MK, Norberg E, Pedersen J, Christensen LG (2008): Invited review: Crossbreeding in dairy cattle: A Danish perspective. *Journal of Dairy Science* 91, 4116–4128.
- Wright VJ (2012): Masterful care of the aging triathlete. *Sports Medicine and Arthroscopy Review* 20, 231–236.

Received: 2016–04–16

Accepted after corrections: 2016–07–11

Corresponding Author:

Sabine Kaessmeyer, Freie Universitat Berlin, Institut fur Veterinar-Anatomie, Koserstr. 20, 14195 Berlin, Germany
E-mail: sabine.kaessmeyer@fu-berlin.de