

## Pectus excavatum in a cat: a case report

R. YAYGINGUL, B. KIBAR, I. SUNER, A. BELGE

Faculty of Veterinary Medicine, Adnan Menderes University, Aydin, Turkey

**ABSTRACT:** This case report aims to clinically and radiologically describe a case of feline pectus excavatum and to evaluate the treatment results. An 8-month-old female cat weighing 3.2 kg was presented to the Surgery Clinic, Faculty of Veterinary Medicine, Adnan Menderes University with respiratory distress. Following radiographic and clinical examinations, the condition was diagnosed as pectus excavatum. Surgical correction was performed using a U-shaped external splint. Post-operative thoracic radiography showed that the concavity of the sternum was reduced. The splint was removed five weeks post-surgery. Two months after surgery, the cat was clinically normal.

**Keywords:** cat; pectus excavatum; external splint; surgical correction

Pectus excavatum (PE) or funnel chest is an uncommon congenital anomaly of the chest wall, characterised by the dorsal deviation of the caudal sternum and associated costal cartilages or a ventral to dorsal narrowing of the entire thorax (Orton 2003; Fossum 2007). The aetiology of the condition is unclear and may well involve multiple causes. Current theories including shortening of the central tendon of the diaphragm, abnormalities in intrauterine pressure and congenital deficiency of the musculature in the cranial portion of the diaphragm (Shires et al. 1988; Fossum et al. 1989; Boudrieau et al. 1990). This defect has been previously reported in dogs (Ellison and Halling 2004; Rahal et al. 2008; Singh 2013) and cats (Risselada et al. 2006; Yoon et al. 2008; Mestrinho et al. 2011) but it is considered to be an uncommon abnormality. The main clinical signs are respiratory distress, exercise intolerance, coughing, cardiac murmur or cyanosis dependent on the severity of the disease (Shires et al. 1988; Fossum et al. 1989; Boudrieau et al. 1990). Diagnosis is based on clinical and radiographic examination, with identification of the sternum deformity and decreased caudal thoracic space (Orton 2003). Treatment for pectus excavatum varies from conservative to surgical depending on the degree of deformity and significance of clinical findings (Ellison and Halling 2004). This case report aims to clinically and radiologically describe the case of feline pectus excavatum and to evaluate the treatment results.

### Case description

The study was performed on an 8-month-old female cat with a body weight of 3.2 kg presented to the Surgery Clinic, Faculty of Veterinary Medicine, Adnan Menderes University with respiratory distress. Medical history revealed that the respiratory distress had persisted for a long period of time and also uncovered a murmur sound during respiration. Blood values were within physiological ranges. Clinical examination revealed a marked inward deformity in the caudal sternum. Thoracic radiographic examination revealed a dorsal displacement of the caudal sternebrae (Figure 1A). Frontosagittal index (FSI) and vertebral index (VI) values were calculated as previously described (Fossum et al. 1989). The FSI value was 1.5 (reference interval 0.3–1.3) and VI value was 6.5 (reference 12.6–18.8). A diagnosis of PE with marked dorsal deviation of the caudal aspect of the sternum was made (Figure 1B). Due to its young age, a decision was made to treat the cat using a U-shaped external splint. Preoperatively, a U-shaped, two-sided splint made of PVC material was prepared by making holes at 1 cm intervals to include the sternum (Figure 2A). The patient was positioned in dorsal recumbency under general anaesthesia. Sutures (1 polypropylen, Ethicon, USA) were passed under the internal surface of the sternum starting from the caudal xiphoida (Figure 1B).

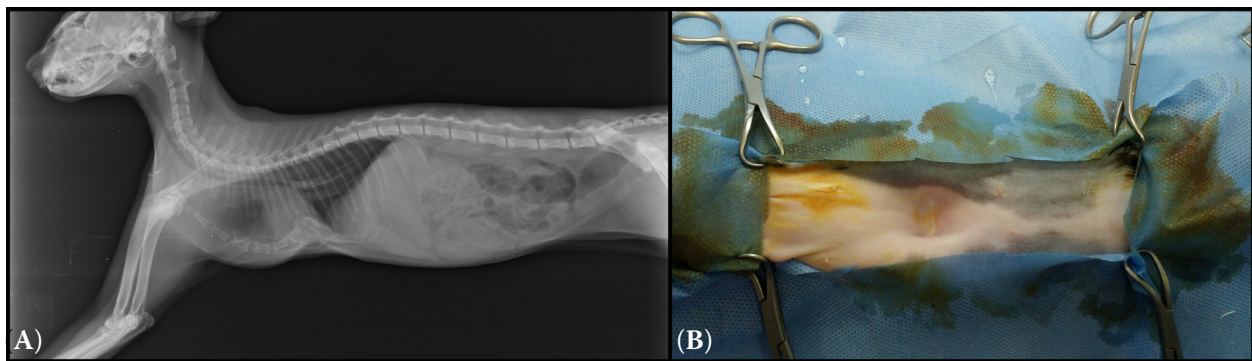


Figure 1. (A) Preoperative lateral radiographic view; (B) dorsal deviation of the caudal aspect of the sternum

Sutures ends were left long and tagged with mosquito haemostats (Figure 2B). All stay sutures were passed through the holes on the splint using an 18-gauge needle and then tied securely. The edges of the splint were padded. A bandage was applied lightly to cover the splint and changed every week. Cefazolin sodium (Iespor® I.E Ulagay, Turkey, 25 mg/kg, intramuscularly) was given for 10 days post-operatively and meloxicam (Bavet Meloxicam®, Bavet, Turkey 0.2 mg/kg subcutaneous), analgesic for five days post-operatively. The respiratory distress improved after the operation. The splint was removed five weeks post-surgery. After removal of the splint, normal thoracic depth was observed in physical and radiographic examinations (Figure 2C). Frontosagittal and vertebral indices were 1.2 and 10.6, respectively.

## DISCUSSION AND CONCLUSIONS

Pectus excavatum (PE) represents a depression in the anterior chest wall resulting from a dorsal deviation of the sternum (Singh et al. 2013). The diagnosis of PE is based on thoracic shape and radiographic changes. Objective assessment of the deformity may be determined by measuring

the frontosagittal and vertebral index on thoracic radiographs. This determination may aid in the objective assessment of improvement of thoracic diameters after surgery (Fossum 1989; Cho et al. 2012). In the present case report, preoperative and postoperative frontosagittal and vertebral indices were determined to be 1.3, 6.8 and 1.5, 10.6, respectively. The radiological measurements in this case were indicative of moderate to severe PE.

The skeletal deformity in PE necessitates surgical repair to allow the cardiopulmonary system to return to normal function. Three types of surgical repair for PE have been described in cats and dogs: external splinting (Fossum et al. 1989; McAnulty and Harvey 1989; Crigel and Moissonnier 2005), internal splinting (Soderstrom et al. 1995; Risselada et al. 2006) and longitudinal sternebrial pinning combined with external splinting (Crigel and Moissonnier 2005). In young cats, the costal cartilages and sternum are flexible and the thorax can be reshaped by applying a permanent traction to the sternum with an external splint (Fossum et al. 1989). The goal of this technique is to pull the sternum outward, keeping it in that position until ossification and bone maturation occurs. In the external splinting type, mouldable splinting material is used to contour a U-shaped or V-shaped splint (Rahal

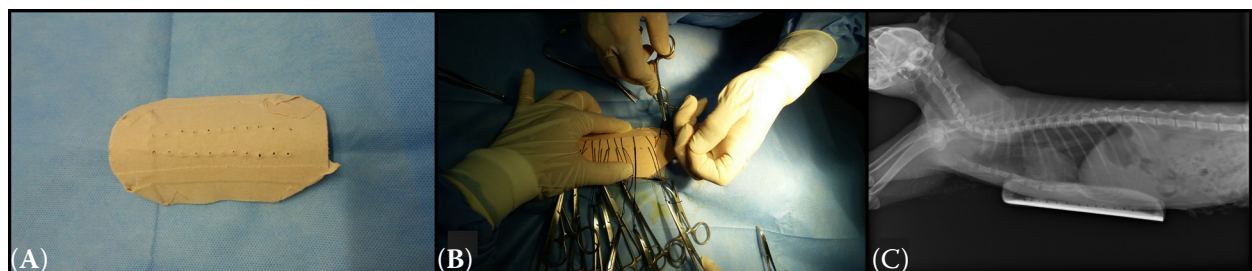


Figure 2. (A) The U-shaped, two-sided splint made of PVC material; (B) intraoperative view; (C) postoperative lateral radiographic view

doi: 10.17221/285/2015-VETMED

et al. 2008). In the present case report, a U-shaped external splint made of a PVC casting material was used. Prior to surgery, the U-shaped external splint was contoured to the normal shape of the cat's thorax. The cat was positioned in dorsal recumbency. Sutures were placed around the sternum. Suture ends were passed through the holes of the external splint and tied to the splint. The splint was left in place for five weeks. The respiratory distress improved substantially after the operation. The most frequent intraoperative complications reported were damage to the internal thoracic vessels, heart, or lungs during the passage of the needle around the sternum (Singh et al. 2013); fatal re-expansion due to pulmonary oedema (Soderstrom et al. 1995); and postoperative skin abrasions, suture abscesses, and dermatitis (Fossum et al. 1989). In our case, dermatitis and suture abscesses were observed. These regions were controlled regularly. During these controls, the region was cleaned with an antiseptic solution. The splint was removed five weeks post-surgery. Two months after surgery, the cat was clinically normal. In conclusion, this case report describes the successful surgical correction of pectus excavatum using a PVC external splint in the cat.

## REFERENCES

- Boudrieau RJ, Fossum TW, Rudy RL, Hartsfield SM, Hobson HP (1990): Pectus excavatum in dogs and cats. *Compendium on Continuing Education for the Practicing Veterinarian* 12, 341–354.
- Cho SJ, Hong S, Chung YH, Kim O (2012): Radiological assessment of pectus excavatum in a Pekingese dog. *Korean Journal of Veterinary Service* 35, 251–254.
- Crigel MH, Moissonnier P (2005): Pectus excavatum surgically repaired using sternum realignment and splint techniques in a young cat. *Journal of Small Animal Practice* 46, 352–356.
- Ellison G, Halling KB (2004): Atypical pectus excavatum in two Welsh terrier littermates. *Journal of Small Animal Practice* 45, 311–314.
- Fossum TW, Boudrieau RJ, Hobson HP, Rudy RL (1989): Surgical correction of pectus excavatum, using external splintage in two dogs and a cat. *Journal of the American Veterinary Medical Association* 195, 91–97.
- Fossum TW (2007): Surgery of the lower respiratory system. In: Fossum TW (ed.): *Small Animal Surgery*. 3<sup>rd</sup> ed. Mosby, St Louis. 867–895.
- McAnulty JF, Harvey CE (1989): Repair of pectus excavatum by percutaneous suturing and temporary external coaptation in a young cat. *Journal of the American Veterinary Medical Association* 194, 1065–1067.
- Mestrinho LA, Ferreira CA, Lopes AM, Niza MMRE, Hammaide AJ (2011): Open surgical correction combined with an external splint for correction of a non-compliant pectus excavatum in a cat. *Journal of Feline Medicine and Surgery* 14, 151–154.
- Orton EC (2003): Thoracic wall. In: Slatter D (ed.): *Textbook of Small Animal Surgery*. 3<sup>rd</sup> ed. Saunders, Philadelphia. 373–387.
- Rahal SC, Morishin MM, Hatschbach E, Machado VMV, Aptekmann KP, Correa TP (2008): Pectus excavatum in two littermate dogs. *Canadian Veterinary Journal* 19, 880–884.
- Risselada M, de Rooster H, Liuti T, Polis I, van Bree F (2006): Use of internal splinting to realign a noncompliant sternum in a cat with pectus excavatum. *Journal of the American Veterinary Medical Association* 228, 1047–1052.
- Shires PK, Waldron DR, Payne J (1988): Pectus excavatum in three kittens. *Journal of the American Animal Hospital Association* 24, 203–208.
- Singh M, Parrah JD, Maulvi BA, Athar H, Kalim MO, Dedmari FH (2013): A review on pectus excavatum in canines; a congenital anomaly. *Iranian Journal of Veterinary Surgery* 8, 59–63.
- Soderstrom MJ, Gilson SD, Gulbas N (1995): Fatal reexpansion pulmonary edema in a kitten following surgical correction of pectus excavatum. *Journal of the American Animal Hospital Association* 31, 133–136.
- Yoon HY, Mann FA, Jeong SW (2008): Surgical correction of pectus excavatum in two cats. *Journal of Veterinary Science* 9, 335–337.

Received: 2015–12–30

Accepted after corrections: 2016–05–06

Corresponding Author:

Rahime Yaygingul, Adnan Menderes University, Faculty of Veterinary Medicine, Department of Surgery, Aydin, Turkey  
E-mail: ryaygingul@adu.edu.tr

## **THE VETERINARY BIOTECHNOLOGY, EPIDEMIOLOGY AND FOOD SAFETY NETWORK (CENTAUR)**

The CENTAUR network aims at upgrading the standards of economically significant priority animal diseases control in the region with particular emphasis on transboundary animal diseases, animal health and consumer protection.

The CENTAUR is willing to achieve it through dissemination of scientific information, training, links with the international centres of excellence and cooperation. The important task is also to present the problems, personalities, institutions, and scientific achievement of the region. Efficient utilization of Internet, e-mail and improvement in English language proficiency is followed, too.

Under the CENTAUR network the CENTAUR NEWSLETTER FLASH INFORMATION (CNFI), an international electronic bulletin (ISSN 1213-368X), is published, providing subscribers with instant information in the form of e-mail messages relating to fields of interest which subscribers define themselves during the process of registration. CNFI covers global animal disease-related events and is distributed to the registered readers from all over the world. The number of subscribers has been growing rapidly and new registrations are always welcome. More than 1200 registered members of the CENTAUR network from 70 countries receive the e-mail information at present. The web page <http://centaur.vri.cz> is recently visited by colleagues from countries of all continents.

The forms of CNFI are as follows:

E-MAIL MESSAGES are distributed to field specific registered members. Sometimes identical information is distributed to more fields of interest. Therefore second mail with identical subject and time of dispatching should not be opened but immediately deleted.

CNFI BULLETIN: approximately 10 issues per year with general information for the CENTAUR network members are distributed to all registered addresses as an attachment to e-mail. This bulletin is also available for downloading from the CENTAUR web page <http://centaur.vri.cz>

CENTAUR network members are welcome as authors of original papers or reviews submitted for publication in an international peer reviewed journal for veterinary medicine and biomedical sciences *Veterinarni medicina*, indexed in the Web of Science, Current Contents and other databases. Papers published in this journal are free in full text at <http://vetmed.vri.cz>

CENTAUR network members can request the Editor for search from the published papers if their intentions are oriented towards contributions for CNFI or submission the manuscript for publication in the journal *Veterinarni medicina*.

CNFI subscription is free. Register your "fields of interest" according to the instructions available at [http://centaur.vri.cz/default.asp?page=cent\\_reg.asp](http://centaur.vri.cz/default.asp?page=cent_reg.asp) and you will receive instant confirmation of your choice by e-mail. To unsubscribe or change the selected fields of interest, send an e-mail to the CNFI editor <[hruska@vri.cz](mailto:hruska@vri.cz)>. Contributions, comments and requests of the subscribers are welcome.

CNFI and the CENTAUR network are your tools!