

Investigations on the postnatal development of the foliate papillae using light and scanning electron microscopy in the porcupine (*Hystrix cristata*)

S. YILMAZ¹, A. AYDIN², G. DINC¹, B. TOPRAK³, M. KARAN¹

¹Veterinary Faculty, Firat University, Elazig, Turkey

²School of Medicine, Adiyaman University, Adiyaman, Turkey

³Etlik Central Veterinary Control and Research Institute, Ankara, Turkey

ABSTRACT: In this study SEM and light microscopy were used to investigate the structure of the foliate papillae in the porcupine. The foliate papillae consisted of about 10 or 11 clefts. The length of the foliate papillae averaged 2.79 mm and its width averaged 863 μm . Taste buds were located intraepithelial in the basal half of the papilla grooves (*sulcus papillae*). Every wall on each fold harboured from five to nine taste buds. There were two different cell types of taste buds: one stained light (*epitheliocytus sensorius gustatorius*), and the other dark (*epitheliocytus sustentans*). The length and width of the taste buds averaged 190.5 μm and 86 μm , respectively. The ratio of the length to the width of taste buds was 2.21. The average depth of the papilla grooves was 1763 μm and its epithelial thickness was 235.5 μm . In scanning electron microscopy, the thickness of the epithelial cell borders was apparent at higher magnifications and there micro-ridges and micro-pits were apparent on the surfaces of these cells.

Keywords: porcupine; *Hystrix cristata*; foliate papillae; scanning electron microscope (SEM)

Several studies have examined the structure of the taste buds in rodents (Hamed et al. 1980; Hosley and Oakley 1987; Smith and Miller 1987; Iwasaki et al. 1996, 1997). In a further study (Kubota et al. 1966) the foliate papillae are mentioned, but there is no further detailed information.

The foliate papillae are located between the body and radix of the tongue, in front of the arcus glossopalatina on the postero-lateral sides of the tongue and opposite the molar teeth in rats, mice and in hamsters (Miller and Chaudry 1976; Gude et al. 1982; Miller and Smith 1984, 1988; Paulson et al. 1985; Royer and Kinnamon 1988; Toprak and Yilmaz 2007). Foliate papillae are located vertically to the tongue length axis and are parallel to the mucosa folds (Kobayashi 1990, 1992).

The structure of the foliate papillae was studied in the flying squirrel (Emura et al. 1999), in rabbits (Kobayashi 1992) and in mice (Paulson et al. 1985; Toprak and Yilmaz 2007) using SEM.

The purpose of this study was to investigate, using SEM and light microscopy, the structure of the foliate papillae in the porcupine.

MATERIAL AND METHODS

Five adult porcupines (three males and two females) were used in this study. They were captured and seriously injured by villagers in Eastern Anatolia (Turkey) and anaesthetised by an overdose of penthotal (sodium penthotal) anaesthetic (10 ml/kg). Euthanasia of the animals was carried out according to local ethical committee regulations. For the light microscopic examination, the area where the foliate papillae were found was fixed with a 10% formalin solution. After an alcohol and xylol series papillae samples were processed routinely and embedded in paraffin and sectioned at 5–7 μm . Sagittal cuts from the papillae were stained using haematoxylin-eosin (Luna 1968). For the scanning electron microscopic examination, tongue samples were immersed in a 3% glutaraldehyde solution with phosphate buffer (pH 7.3). After rinsing in buffer, tissues were post-fixed in 1% osmium tetroxide at 37 °C for one and a half hours. After post-fixation, the samples were placed in 3M NHCl at 60 °C for 20 min to remove the extracellular mucus




Figure 1. Clefts of the foliate papillae. 12KV × 35 BAR: 500 μm 0000 JSM-5600

from the surfaces of the tissues. The samples were dehydrated in an alcohol and amyl acetate series and dried using a Polaron CPD 7501 critical-point-dryer (VGMicrotech, East Sussex, UK). Specimens were then coated with gold and examined under a Jeol JSM 5600 scanning electron microscope (Jeol Ltd., Tokyo, Japan) at 5–15 kV.

RESULTS

The tongue averaged 6.7 cm in length and 1.6 cm width in the corpus region. The median sulcus was

deeper in the anterior third than the middle third of the tongue; the posterior third had a rare median sulcus. The dorsal surface of the tongue was covered with non-keratinised stratified squamous epithelium underlined by *lamina propria* and a muscular layer.

The foliate papillae were located on the postero-lateral borders of the tongue. They contained approximately 10 or 11 clefts. The length of the foliate papillae averaged 2.79 mm and its width was 863 μm (Figure 1). Taste buds were located intraepithelial in the basal half of the papilla grooves (*sulcus papillae*).

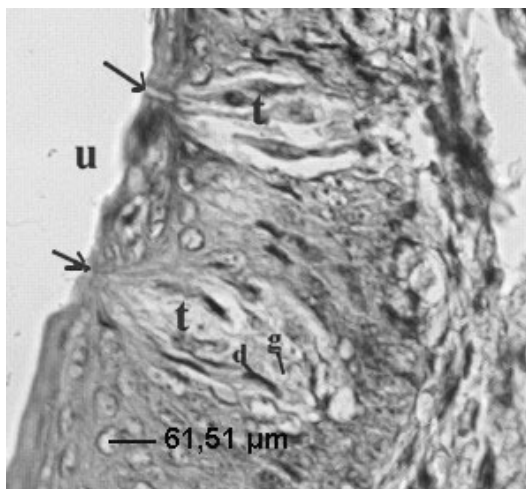


Figure 2. Taste buds (t), groove of the papilla (u), taste pores (arrow) and taste buds cells [light (g) and dark (d)]; H.E. × 200

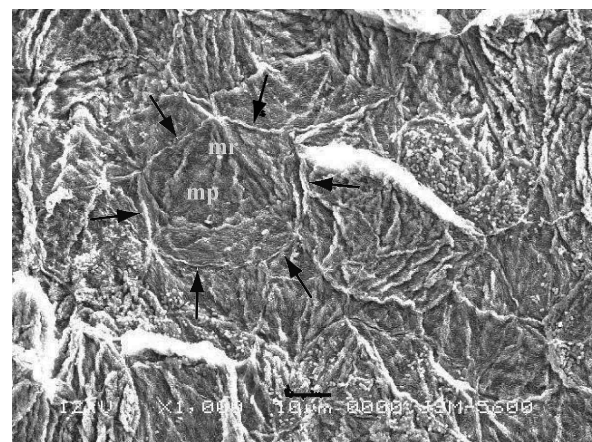


Figure 3. The appearance of the foliate papilla at higher magnification. Micro-ridge (mr), micro-pit (mp) and cell borders (arrows), 12KV × 1000 BAR: 10 μm 0000 JSM-5600

Every wall of folds contained from five to nine taste buds. There were two different types of cells comprising the taste buds; one which stained light (*epitheliocyttusensoriusgustatorius*) and another which stained dark (*epitheliocyttusustentans*) could be distinguished (Figure 2). The length and width of taste buds averaged 190.5 μm and 86 μm , respectively. The rate of the length to the width of taste buds was calculated to be 2.21.

The average depth of papilla grooves was 1763 μm and the epithelial thickness was 235.5 μm . With the use of scanning electron microscopy, the foliate papillae were clearly distinguished. The thickness of the epithelial cell borders was apparent at higher magnifications and micro-ridges and micro-pits were apparent on the surface of these cells (Figure 3).

DISCUSSION

The number of foliate papillae ridges has been reported as seven or eight rows by Kubota and Togowa (1966) in the Japanese dormouse, 34 rows by Emura et al. (1999) in flying squirrels, 15–20 rows by Kobayashi (1992) in rabbits, and seven to eight rows by Paulson et al. (1985), four to six rows by Toprak and Yilmaz (2007) and four to five rows by Royer and Kinnamon (1988) in mice, and 20 rows by Kubota et al. (1966) in porcupines. In this study, 10–11 foliate papillae ridges were observed in contrast to the report of Kubota et al. (1966).

Kobayashi (1992) reported that the width of papillae ridges was 220 μm in rabbits and that the width of each groove was about 30 μm . Toprak and Yilmaz (2007) reported that the ridges of foliate papillae increased to 178 μm in length and 157 μm in width, the depth of grooves was 131 μm and the width of the grooves was 24 μm by the 90th day of age of the animal. Royer and Kinnamon (1988) observed that the average depth of the papillae grooves was 150 μm . In this study, foliate papillae were found to be 2.79 mm in length, 863 μm in width and the depth of grooves was 1763 μm .

State et al. (1974) detected five different type cells in the taste buds using light microscopic examination of the albino rat. Using light microscopy, Toprak and Yilmaz (2007) reported that dark- and light-stained taste bud cells were also present in mice. Royer and Kinnamon (1988) reported different taste bud cell types such as dark, light and intermediate in mice using electron microscopy.

The results of this study are similar to those of Toprak and Yilmaz (2007).

The length of foliate papillae taste buds was reported to be 100–125 μm in hamsters (Miller and Chaudry 1976) and 42.21 μm in mice (Toprak and Yilmaz 2007). The width of the foliate papillae taste buds was reported to be 50–80 μm in hamsters (Miller and Chaudry 1976) and 27–28 μm in mice (Toprak and Yilmaz 2007). In this study, the length and width of taste buds were 190.5 μm and 86 μm , respectively.

It has been reported that the borders of surface cells were clear (Svejda and Janota 1974; Toprak and Yilmaz 2007) and that there were many micro-ridges on surface cells (Agungpriyono et al. 1995; Utiyama et al. 1995; Toprak and Yilmaz 2007). The findings of this study are in agreement with these earlier results.

In this study, light and scanning electron microscopy was used to determine the structures of the papillae foliate in porcupines. It is hoped that the results presented here may contribute to enhancing our understanding of these structures.

REFERENCES

- Agungpriyono S, Yamado J, Kitamura N, Nisa C, Sigit K, Yamamoto Y (1995): Morphology of the dorsal lingual papillae in the lesser mouse deer, *Tragulus javanicus*. *Journal of Anatomy* 187, 635–640.
- Emura S, Tamada A, Hoyokowa D, Chen H, Jamali M, Taguchi H, Shoumura S (1999): SEM Study on the dorsal lingual surface of the flying squirrel (*Petaurista leucogenys*). *Annals of Anatomy* 181, 495–498.
- Gude WD, Cosgrove GE, Hirsch GP (1982): Digestive System. *Histological Atlas of the Laboratory Mouse*. Plenum Press, New York and London. 17–18.
- Hamed MS, Serafy AK, El-Eishi IH (1980): Histological and histochemical study on the development of foliate papillae in guinea pigs. *Acta Anatomica* 106, 101–107.
- Hosley MA, Oakley B (1987): Postnatal development of the vallata papilla and taste buds in rats. *Anatomical Record* 218, 216–222.
- Iwasaki S, Yoshizawa H, Kawahara I (1996): Study by scanning electron microscopy of the morphogenesis of three types of lingual papilla in the mouse. *Acta Anatomica* 157, 41–52.
- Iwasaki S, Yoshizawa H, Kawahara I (1997): Study by scanning electron microscopy of the morphogenesis of three types of lingual papilla in the rat. *Anatomical Record* 247, 528–541.

- Kobayashi K (1990): Three-dimensional architecture of connective tissue core of the lingual papillae in the guinea pig. *Anatomy and Embryology* 182, 205–213.
- Kobayashi K (1992): Stereo architecture of the interface of the epithelial cell layer and connective tissue core of the foliate papilla in the rabbit tongue. *Acta Anatomica* 143, 109–117.
- Kubota K, Togowa S (1966): Comparative anatomical and neurohistological observations on the tongue of japanese dormouse (*Glirus Japonicus*). *Anatomical Record* 154, 545–552.
- Kubota K, Fukuda N, Asakura S (1966): Comparative anatomical and neurohistological observations on the tongue of the porcupine (*Hystrix cristata*). *Anatomical Record* 155: 261–268.
- Luna LG (1968): *Manuel of Histologic Staining Methods of the Armed Forces Institute of Pathology*. 3rd ed. Mc. Graw-Hill Book Company, Toronto, London.
- Miller RL, Chaudry AP (1976): Comparative ultrastructural of vallate, foliate and fungiform taste buds of golden Syrian hamster. *Acta Anatomica* 95, 75–92.
- Miller IJ, Smith DV (1984): Quantitative taste bud distribution in the hamster. *Physiology and Behavior* 32, 275–285.
- Miller IJ, Smith DV (1988): Proliferation of taste buds in the foliate and vallate papillae of postnatal hamsters. *Growth, Development and Aging* 52, 123–131.
- Paulson B, Hayes T G, Sucheston ME (1985): Scanning electron microscope study of tongue development in the CD-1 mouse fetus. *Journal of Craniofacial Genetics and Developmental Biology* 5, 59–73.
- Royer SM, Kinnamon JC (1988): Ultrastructure of mouse foliate taste buds: Synaptic and nonsynaptic interactions between taste cells and nerve fibers. *Journal of Comparative Neurology* 270, 11–24.
- Smith DV, Miller Jr. IJ (1987): Taste bud development in hamster vallate and foliate papillae. *Annals of the New York Academy of Sciences* 510, 632–634.
- State FA, El-Eishi HI, Naga IA (1974): The development of taste buds in the foliate papillae of the albino rat. *Acta Anatomica* 89, 452–460.
- Svejda J, Janota M (1974): Scanning electron microscopy of the papillae foliate of the human tongue. *Oral Surgery* 37, 208–216.
- Toprak B, Yilmaz S (2007): Investigations on postnatal development of the foliate papillae by the light and scanning electron microscopy in the white laboratory mice. *Revue de Médecine Vétérinaire* 158, 479–482.
- Utiyama C, Watanabe I, Konig B, Koga LY, Semprini M, Tedesco RC (1995): Scanning electron microscopic study of the dorsal surface of the tongue of calomys callosus mouse. *Annals of Anatomy* 177, 569–572.

Received: 2013–01–13

Accepted after corrections: 2013–06–06

Correspondin author:

Prof. Dr. Ali Aydin, Firat University, Veterinary Faculty, Department of Anatomy, 23119-Elazig, Turkey
Tel. +90 424 237 0000/4042; Fax: +90 424 238817, E-mail: aydina@firat.edu.tr
