

Quantitative analysis of hydrocephalic ventricular alterations in Yorkshire terriers using magnetic resonance imaging

D.-C. WOO¹, C.-B. CHOI², J.-W. NAM³, K.-N. RYU², G.-H. JAHNG⁴, S.-H. LEE³,
D.-W. LEE¹, S.-Y. KIM¹, H.-Y. KIM³, K.-J. AHN¹, B.-Y. CHOE¹

¹College of Medicine, The Catholic University of Korea, Seoul, Republic of Korea

²Kyunghee University Medical Center, Seoul, Republic of Korea

³College of Veterinary Medicine, Konkuk University, Seoul, Republic of Korea

⁴East-West Neo Medical Center, Kyung-Hee University, Seoul, Korea

ABSTRACT: The purpose of this work was to evaluate hydrocephalic ventricular changes using three quantitative analysis methods. The height, area and volume of the ventricles and brain were measured in 20 Yorkshire terriers (10 normal and 10 hydrocephalic dogs) using low-field MR imaging (at 0.2 Tesla). All measurements were averaged and the relative ventricle size was defined as a percentage (percent size of the ventricle/size of the brain). The difference between normal and hydrocephalic dogs was statistically significant for the average of each ventricle as well as for the percentage value. Five hydrocephalic symptoms were identified: circling, head tilting, seizures, ataxia, and strabismus. With respect to height, area and volume of the brain/ventricle, the difference between normal and hydrocephalic dogs was not significant. The ventricle/brain with height (1D) was related to the area (2D) and volume (3D). The correlations with area and volume were as good as the ventricle/brain height ratio in the case of hydrocephalic dogs. Therefore, one-, two- and three-dimensional quantitative methods may be complementary. We expect that the stage of hydrocephalic symptoms can be classified if statistical significance for ventricular size among symptoms is determined with the analysis of a large number of hydrocephalic cases.

Keywords: hydrocephalus; ventricles; magnetic resonance imaging; Yorkshire terrier

Magnetic resonance imaging (MRI) can provide anatomical and morphological information and MR imaging has been used to evaluate central nervous system (CNS) diseases of humans and animals.

Hydrocephalus is caused by blockage of cerebrospinal fluid (CSF) outflow in the ventricles or in the subarachnoid space by the brain. Alternatively, the condition may result from an overproduction of

CSF fluid, from a congenital malformation blocking normal drainage of the fluid, or from complications of head injuries or infections (Horbar et al., 1983; Gaston and Jones, 1989; Del Bigio, 1993; Emerson et al., 1994; Braun et al., 1997). Furthermore, many veterinarians have an interest in hydrocephalus as the condition is relatively common in certain canine breeds and has been found in clinically healthy

Supported by a grant of the Seoul R and BD Program (10550), the Korea Health 21 R and D Project, Ministry of Health and Welfare, Republic of Korea (A081057), a grant (R01-2007-000-20782-0) from the Purpose Basic Research Grant of the KOSEF, a Korea Research Foundation Grant funded by the Korean Government (KRF-2008-313-D01324), the program of Basic Atomic Energy Research Institute (BAERI), which is a part of the Nuclear R and D Programs funded by the Ministry of Education, Science and Technology (MEST) of Korea and the Seoul Fellowship from the Seoul metropolitan government.

adult beagles (Vullo et al., 1997; Esteve-Ratsch et al., 2001). Depending on the shape of the canine head, the main anatomical differences affect brain shape, weight and size, including the size of the ventricles. Murata et al. (1981) and Vullo et al. (1997) have described variations in brain shape, weight, and size but these parameters were not the subject of previous studies. However, enlargement of ventricles and asymmetry have been frequently observed in toy-breed dogs, independent of the head shape (Kii et al., 1997, Esteve-Ratsch et al., 2001).

Until now, various approaches for the measurement of hydrocephalic ventricles in canine breeds have been attempted using CT/MRI tomography (Kii et al., 1997, 1998; Nykamp et al., 2001). The imaging modalities have been generally processed by analysis of the morphology alone, such as the ventricle size and volume. It has been reported that the ratio of the ventricle height to brain height was 80% (reference range, 0–14%) and the ratio of the ventricle area to the hemisphere brain was 7.1% (normal range, 3.0–7.6%) (Vullo et al., 1997; Esteve-Ratsch et al., 2001). However, an evaluation and comparison of the analysis methods have not yet been reported. Therefore, the purpose of this study was to evaluate quantitatively ventricular alterations of hydrocephalic Yorkshire terriers to calibrate the gauge of the ventricular height, area and volume.

MATERIAL AND METHODS

Animals

Twenty Yorkshire terrier dogs (age range, 2–8 years) that included 10 dogs with hydrocephalic symptoms and 10 dogs without symptoms were used in the study without sex discrimination. All of the symptoms of each hydrocephalic dog were recorded and the age-matched dogs without any symptoms were involved for the comparative study between normal and hydrocephalic dogs. This study was approved by the Institutional Animal Care and Use Committee at the College of Veterinary Medicine, Konkuk University (IACUC No.: KU09047). Examination of the hydrocephalic dogs was performed at the Doctor's Pet Hospital in Seoul, Korea over a five-year period (2004–2009). Although following a physical examination with a hemogram and blood chemistry – complete blood count (CBC), total protein (TP), aspartate aminotransferase (AST),

alanine aminotransferase (ALT), blood urea nitrogen (BUN) and creatinine (CREA) – were performed, all values were consistent with healthy conditions and the difference between dogs with and without symptoms was also not significant.

Data acquisition

MR experiments were conducted using a 0.2 tesla system (E-scan, Esaote, Genoa, Italy) with human knee coils. Anesthesia was induced with propofol (Anefol, Hana Pham, Korea) which was injected intravenously at a dose of 6 mg/kg. All dogs were intubated and anesthesia was maintained with 1.5% isoflurane (Forane Soln, Choongwae, Korea) in 100% oxygen. Anesthetized dogs were placed in sternal recumbency on the scanning table. Transverse and dorsal T1-weighted MR images were acquired using a repetition time (TR) of 650 ms and an echo delay time (TE) of 25 ms. The slice thickness was 4–6 mm with no gap and the total thickness of images was 4 cm. A total of 6–8 MR image slices were used with a volume of interest (VOI) that covered the whole brain as shown in Figure 1 (a sagittal view). As the brain sizes of the canines were different, the VOI covered changing slice thicknesses and number of slices. Figure 2 shows representative T1-weighted axial images of normal (A) and hydrocephalic (B) dogs at the level of the interthalamic adhesion.

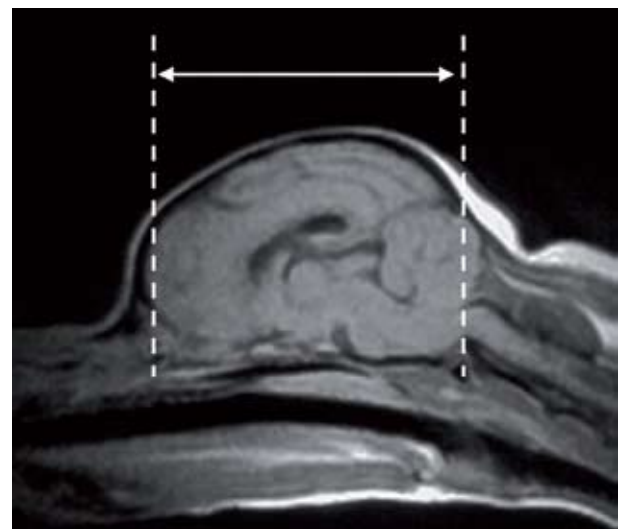


Figure 1. A sagittal view (T1-weighted image: spin echo, TR: 650 ms, TE: 35 ms) of a Yorkshire terrier brain. Transverse images with no gap and 6–8 slices were scanned in this indicated range

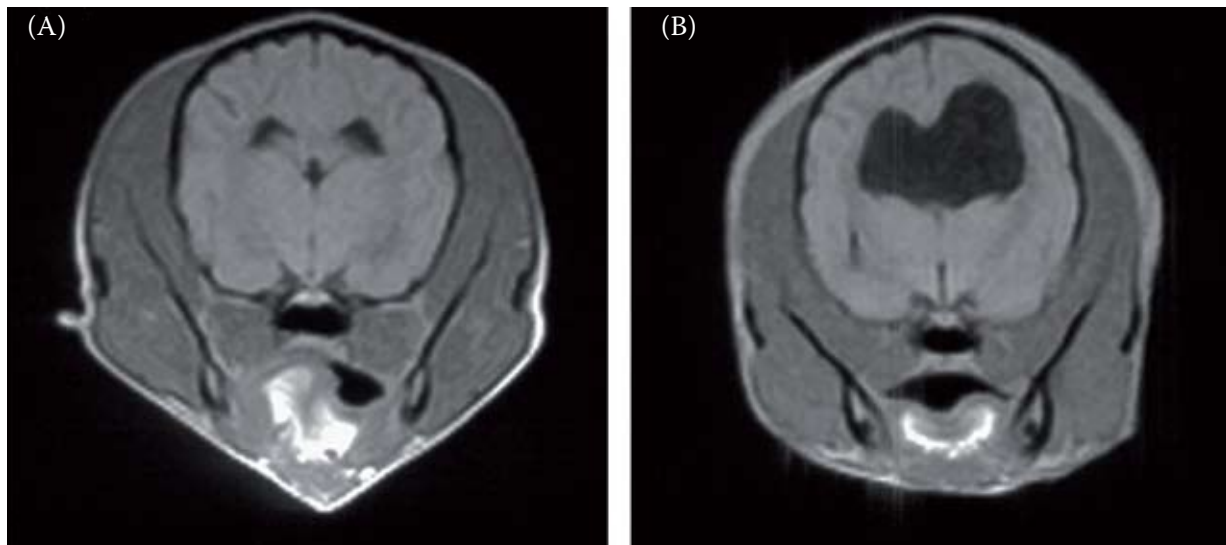


Figure 2. Transverse T1-weighted images of normal (A) and hydrocephalic (B) dogs at the level of the interthalamic adhesion are shown. The ventricle size of a hydrocephalic dog was larger as compared to a normal dog

Analysis

T1-weighted MR images were analyzed across a series of regions of interest (ROI) as illustrated in Figure 3. In order to measure volumes of the whole brain and left and right ventricles, each section was extracted on all T1-weighted MR images as shown in Figure 3A. These results present the volume as “mm³”. Figure 3B

shows that the height (mm) of the brain and the height of the right and left ventricles were measured. The heights and areas of both ventricles were measured at the level of the interthalamic adhesion.

As a next step, the ventricle to brain height ratio (VBHR, ventricle height/brain height × 100), the ventricle to brain area ratio (VBAR, ventricle area/brain area × 100) and the ventricle to brain volume

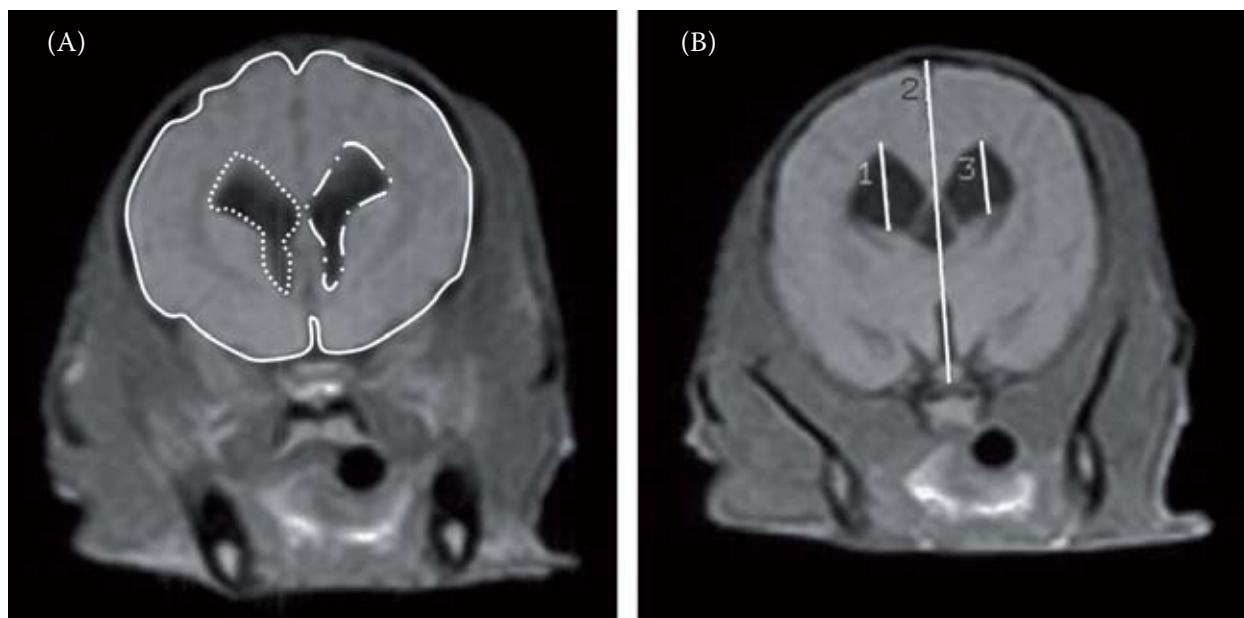


Figure 3. (A) The lateral right and left ventricles (two dashed lines) and the corresponding whole brain (line) were outlined manually. Areas were automatically calculated on the slice of the interthalamic level (the area of the selected region = field of view (FOV)/total pixels in a image × counted pixel number in the selected region). Volumes were measured by summation after multiplying the slice thickness by the calculated area of each image slice. (B) Heights of the right and left ventricles and brain were also gauged at the interthalamic adhesion level

ratio (VBVR, ventricle volume/brain volume $\times 100$) were calculated. Lastly, the comparison between VBHR and VBVR as well as the difference between normal dogs and dogs with hydrocephalus were investigated. In order to calculate the correlation of VBHR-VBAR and VBHR-VBVR, a two simple equations were estimated as following:

$$Y = a_1X + a_2X^2 \quad (1)$$

$$Y = b_1X + b_2X^2 + b_3X^3 \quad (2)$$

where:

X and Y = VBHR and VBAR in eq (1)

X and Y = VBHR and VBVR in eq (2)

The data were analyzed using ImageJ (National Institutes of Health, Bethesda, MD, USA) and SPSS (Windows version 13.0; SPSS, Chicago, IL USA). The data were further analyzed with Student's two-tailed t -test, in order to compare significant differences among the three determined ratios. P -values ≤ 0.05 were considered as statistically significant.

RESULTS

Table 1 shows the heights, areas and volumes for both normal and hydrocephalus cases. Although the height, area and volume of the brain between normal and hydrocephalus dogs were not significantly different (height: $P > 0.8$, area: $P > 0.8$, volume: $P > 0.5$), the measured values of the ventricles were significantly different (all $P < 0.01$).

Body weight, VBHR, VBAR, VBVR and clinical symptoms of each canine are listed in Table 2. Body weight was significantly different between normal dogs and dogs with hydrocephalus ($P < 0.01$). The right and left VBHR, VBAR and VBVR for both normal dogs and dogs with hydrocephalus were measured as shown in Figure 4. The right and left VBHR of normal dogs was $15.06 \pm 4.97\%$ and $17.11 \pm 5.06\%$, respectively. The right and left VBHR of dogs with hydrocephalus was $32.45 \pm 4.44\%$ and $35.45 \pm 7.19\%$, respectively. The right and left VBAR of normal dogs was $2.63 \pm 1.56\%$ and $2.92 \pm 1.57\%$, respectively. The right and left VBAR of dogs with hydrocephalus was $11.85 \pm 7.15\%$ and $11.93 \pm 5.86\%$, respectively. The right and left VBVR of normal dogs was $2.28 \pm 1.32\%$ and $2.43 \pm 1.23\%$, respectively. The right and left VBVR of dogs with hydrocephalus was $9.85 \pm 3.98\%$ and $11.34 \pm 3.71\%$, respectively. The difference between the right and left side in the same group was not significant ($P > 0.1$), and all values of VBHR, VBAR and VBVR were significantly different between dogs with and without hydrocephalus ($P < 0.001$). The VBHR were correlated to VBAR and VBVR as showing Figure 5. The relationship between VBAR and VBHR was $Y = 0.0345X + 0.0111X^2$, $R^2 = 0.763$ and $P < 0.0001$. Also, VBVR-VBHR relationship was $Y = -0.0562X + 0.0129X^2 - 0.00007X^3$, $R^2 = 0.936$ and $P < 0.0001$.

Hydrocephalic symptoms included circling, head tilting, seizures, ataxia, and strabismus. Particularly, all hydrocephalic canines with the exception of one dog (H02) had a circling action.

Table 1. Volume and height in Yorkshire terrier brains and the right and left ventricles: mean values (standard deviation, SD) of normal dogs and dogs with hydrocephalus

		Normal ($n = 10$)	Hydrocephalus ($n = 10$)	P -value*	
Height (mm)	brain	26.94 (4.45)	26.64 (5.27)	0.88969	
	ventricle	right	4.06 (0.98)	8.64 (2.14)	< 0.00001
		left	4.47 (0.98)	9.32 (2.27)	< 0.00001
Area (mm ²)	brain	1430.24 (427.47)	1500.55 (757.77)	0.80117	
	ventricle	right	33.15 (13.03)	170.48 (148.39)	0.00923
		left	37.20 (14.88)	168.69 (130.21)	0.00527
Volume (mm ³)	brain	44 679.80 (13 580.34)	40 121.62 (16 407.67)	0.50716	
	ventricle	right	887.72 (311.53)	4064.94 (2805.44)	0.00224
		left	967.86 (292.04)	4509.62 (2579.46)	< 0.00001

* P -values of the Student's two-tailed t -test between normal and hydrocephalus

Table 2. The weight, VBHR, VBAR, VBVR values and relative clinical symptoms for all of the canines

Canine#	Weight* (kg)	VBHR (%)		VBAR (%)		VBVR (%)		Clinical Symptoms	
		right	left	right	left	right	left		
Normal	N01	3.0	23.13	24.63	5.78	6.05	3.84	3.84	
	N02	3.7	19.87	25.03	3.73	4.29	4.41	4.44	
	N03	2.5	21.09	16.41	4.29	3.50	3.85	2.86	
	N04	3.2	14.54	16.87	1.41	1.21	2.00	1.92	
	N05	2.0	14.36	15.46	2.32	2.52	1.78	1.90	
	N06	2.0	8.19	17.54	1.04	3.40	0.77	2.64	
	N07	2.9	13.37	13.91	1.57	1.65	1.40	1.65	
	N08	2.8	17.12	17.46	2.41	2.92	1.74	2.34	
	N09	3.0	8.35	7.24	1.00	0.62	0.67	0.42	
	N10	3.3	16.00	16.57	2.78	3.03	2.35	2.25	
Hydrocephalus	H01	2.8	27.18	24.79	7.04	4.91	8.09	6.27	circling, head tilt
	H02	3.4	31.54	44.15	7.21	14.3	7.06	15.16	seizure
	H03	2.1	36.34	41.22	14.57	20.73	9.96	14.22	ataxia, circling
	H04	2.2	26.68	22.52	6.99	5.48	5.41	5.09	ataxia, circling
	H05	2.0	31.04	33.10	3.83	3.96	8.22	9.54	ataxia, circling
	H06	1.9	28.42	33.81	6.63	9.53	8.23	9.26	seizure, circling,
	H07	2.5	33.42	42.87	12.87	10.84	8.85	14.32	circling
	H08	1.6	32.69	37.99	14.06	17.45	11.55	14.76	circling, head tilt, strabismus
	H09	1.2	40.22	37.50	27.83	15.61	19.00	14.08	circling, seizure, strabismus
	H10	1.5	36.98	36.60	17.45	16.49	12.12	10.69	circling, seizure, strabismus

#the canines were classified into two groups (normal and hydrocephalus) based on the onset of ventricular expansion and clinical symptoms

*body weight was also significantly different between normal dogs and dogs with hydrocephalus (normal: 2.92 ± 0.58 kg, hydrocephalus: 2.12 ± 0.65 kg, $P < 0.01$)

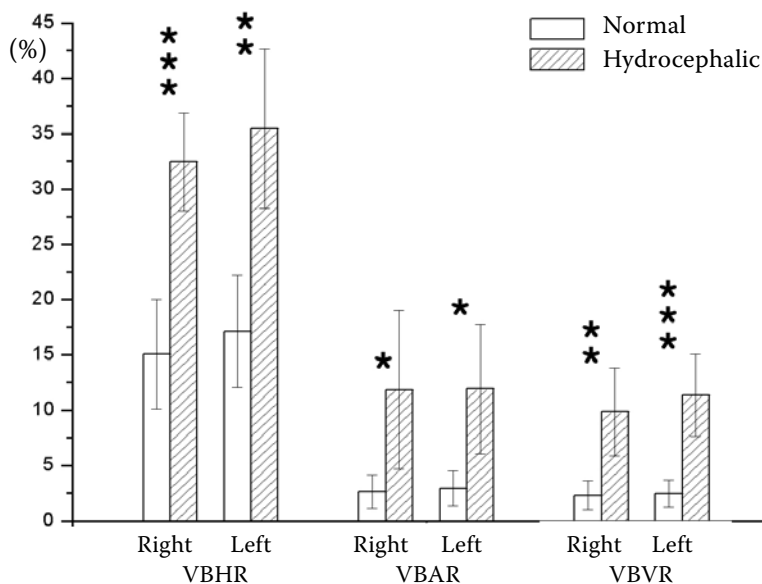


Figure 4. VBHR, VBAR, and VBVR were significantly different between normal ($n = 10$) and hydrocephalic ($n = 10$) dogs

* $P < 0.001$, ** $P < 0.0001$, *** $P < 0.00001$

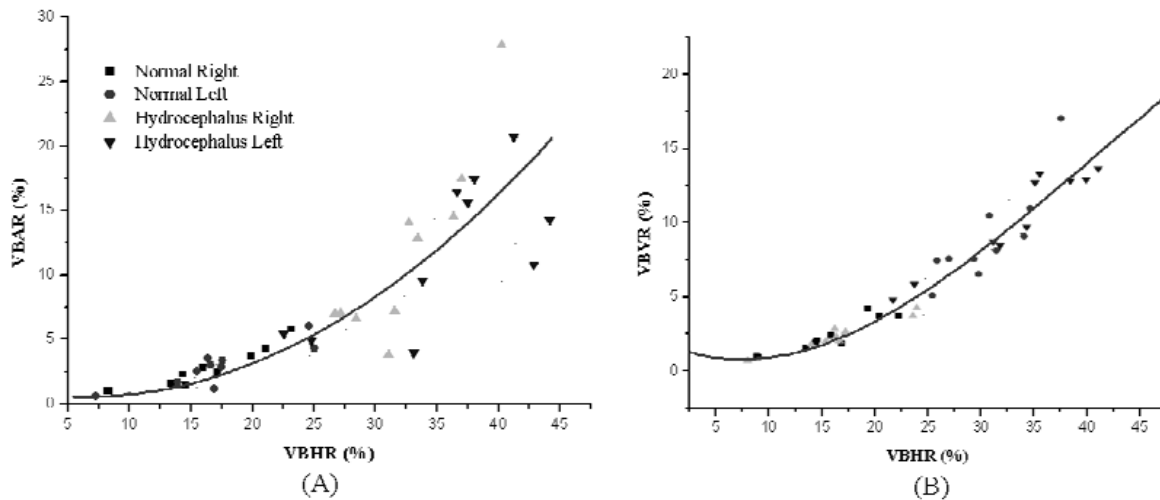


Figure 5. There were positive correlation among VBHR, VBAR and VBVR. (A) The relationship between VBAR and VBHR. $Y = 0.0345X + 0.0111X^2$, $R^2 = 0.763$ and $P < 0.0001$. (B) The relationship between VBVR-VBHR. $Y = -0.0562X + 0.0129 X^2 - 0.00007 X^3$, $R^2 = 0.936$ and $P < 0.0001$

DISCUSSION

Clinically symptomatic hydrocephalus may also occur in particular lines of beagles as a developmental anomaly and in beagle-type mongrels, but symptomatic hydrocephalus does not typically occur in the general beagle population. It has already been reported that the size, symmetry and volume of the lateral ventricles in healthy dogs is variable (Cammermeyer, 1961; Vullo et al., 1997).

In this work, to quantitatively evaluated hydrocephalic ventricular alterations using three analytic methods. Our findings were that normal dogs had $VBHR < 25\%$, $VBAR < 7\%$ and $VBVR < 5\%$ while dogs with hydrocephalus had $VBHR > 20\%$, $VBAR > 7\%$ and $VBVR > 5\%$. These values may enable standards for a hydrocephalic diagnosis to be estimated. However, these values cannot be absolute standards, as several variables will affect the results such as breed, age, sex and ventricular symmetry.

Several studies (Murata et al., 1981; Kii et al., 1997, 1998; Esteve-Ratsch et al., 2001) that have quantitatively measured ventricular alterations of hydrocephalic dogs using height (one-dimensional analysis, 1-D), area (two-dimensional analysis, 2-D) and volume (three-dimensional analysis, 3-D) of the brain and ventricle have been reported. In this work, we confirmed that the three measurement methods had statistical significance. For statistical significance for 1-D, 2-D and 3-D quantitative analysis, P -values of VBHR, VBAR and VBVR were ≤ 0.001 . However, for higher order dimensional

analysis, more data, time and processing stages were required. Therefore, the use of 1-D quantitative analysis that was available for an exact diagnosis of hydrocephalus could save time and effort. The use of 2-D and 3-D quantitative analysis of hydrocephalus may be superior to 1-D analysis in particular cases. In addition, the three methods may be complementary. Kii et al. (1998) has characterized the period of onset of ventricular expansion and developmental change in ventricular volume in a group of beagle-type dogs. Our study demonstrated that the area and volume of the ventricle were correlated to its height as shown in Figure 5.

According to the dog breed, the symptoms and anatomical change of a disorder/disease may be different. Therefore, hydrocephalic alteration of each breed deserves to be investigated. In this work, only one dog breed (Yorkshire terrier) was used and the difference between normal animals and animals with hydrocephalus was statistically significant. If hydrocephalus in another canine breed was investigated, a different pattern of results may be observed. In addition, valuable and helpful information can be provided if the hydrocephalic study is conducted after the stage of the hydrocephalic symptoms is classified (Oi et al., 1991, 1998; Girard and Raybaud, 2001). Although the body weight of hydrocephalic dogs was smaller than that of normal dogs in this study, the decrease in the body weight should be considered as a minor symptom for the diagnosis of canine hydrocephalus because a decrease in body weight can be due to multiple

causes. Therefore, we concentrated on five symptoms found in hydrocephalic canines in Table 2: circling, head tilting, seizure, ataxia, and strabismus. Except for H02, circling was observed in most of dogs. Therefore, circling may be a general symptom in the case of a hydrocephalic dog. In contrast, the hydrocephalic dogs with strabismus (H08, H09, and H10) had a larger ventricle size (VBVR > 10%) compared with the other hydrocephalic dogs. Also, the body weight of these dogs were also lower (< 1.6 kg). Consequently, strabismus may be a symptom of late stage hydrocephalus. However, we were not able to finally determine a correlation between symptoms and ventricular size of canines. Therefore, it needs to classify the stage of the hydrocephalic symptoms as statistically significance of ventricular size among the symptoms is found from an analysis of a sufficient number of hydrocephalic cases.

MR imaging allows exact assessment of ventricle size and shape *in vivo*. Furthermore, advanced MR imaging techniques such as MR spectroscopy, diffusion weighted/tensor and perfusion imaging can identify changes in metabolism, preoperative hemodynamics, and diffusion coefficients. Although several studies (Braun et al., 1997; Corkill et al., 2003; Koudijs et al., 2006; Tarnaris et al., 2009) have already published applications for human hydrocephalus using diffusion and perfusion MR techniques, studies of canine hydrocephalus have not yet been performed. We expect that more innovative results can be obtained if advanced MR techniques are applied to canine studies.

In summary, we have evaluated ventricular alterations due to hydrocephalus in Yorkshire terriers using low-field MR imaging correlated with hydrocephalic symptoms. In addition, we determined that 1-D, 2-D and 3-D quantitative ratios for hydrocephalic ventricle size were significantly higher as compared to normal animals. Thus, these findings can be helpful to analyzing hydrocephalic dogs. Further studies are needed to investigate different dog breeds and the classification of canine hydrocephalus symptom stage.

REFERENCES

- Braun KPJ, Dijkhuizen RM, de Graaf RA, Nicolay K, Vandertop WP, Gooskens RHJM, Tulleken KAF (1997): Cerebral ischemia and white matter edema in experimental hydrocephalus: a combined *in vivo* MRI and MRS study. *Brain Research*, 757, 295–298.
- Cammermeyer J (1961): Frequency of meningoencephalitis and hydrocephalus in dogs. *Journal of Neuropathology and Experimental Neurology*, 20, 386–398.
- Corkill RG, Garnett MR, Blamire AM, Rajagopalan B, Cadoux-Hudson TAD, Styles P (2003): Multi-modal MRI in normal pressure hydrocephalus identifies preoperative haemodynamic and diffusion coefficient changes in normal appearing white matter correlating with surgical outcome. *Clinical Neurology and Neurosurgery*, 105, 193–202.
- Del Bigio MR (1993): Neuropathological changes caused by hydrocephalus. *Acta Neuropathologica*, 85, 573–585.
- Emerson JF, Chen P-C, Shankle WR, Greensite FS, Foltz EL, Lott IT, Nalcioglu O (1994): Cortical CSF volume fluctuations by MRI in brain aging, dementia and hydrocephalus. *Neuroreport*, 5, 1699–1704.
- Esteve-Ratsch B, Kneissl S, Gabler C (2001): Comparative evaluation of the ventricles in the Yorkshire terrier and the German Shepherd dog using low-field MRI. *Veterinary Radiology and Ultrasound*, 42, 410–413.
- Gaston BM, Jones BE (1989): Perinatal unilateral hydrocephalus. *Pediatric Radiology*, 19, 328–329.
- Girard NJ, Raybaud CA (2001): Ventriculomegaly and pericerebral CSF collection in the fetus: early stage of benign external hydrocephalus? *Child's Nervous System*, 17, 237–238.
- Horbar JD, Leahy KA, Lucey JF (1983): Ultrasound identification of lateral ventricular asymmetry in the human neonate. *Journal of Clinical Ultrasound*, 11, 61–69.
- Kii S, Uzuka Y, Taura Y, Nakaichi M, Takeuchi A, Inokuma H, Onishi T (1997): Magnetic resonance imaging of the lateral ventricles in beagle-type dogs. *Veterinary Radiology and Ultrasound*, 38, 430–433.
- Kii S, Uzuka Y, Taura Y, Nakaichi M, Inokuma H, Onishi T (1998): Developmental change of lateral ventricular volume and ratio in beagle-type dogs up to 7 months of age. *Veterinary Radiology and Ultrasound*, 39, 185–189.
- Koudijs SM, van der Grond J, Hoogendoorn MLC, Hulshoff Pol HE, Schnack HG, Witkamp TD, Gooskens RHJM, van Nieuwenhuizen O, Braun KPJ (2006): MRI, volumetry, 1H Spectroscopy, and cerebropetal blood flowmetry in childhood idiopathic anatomic megalencephaly. *Journal of Magnetic Resonance Imaging*, 24, 282–287.
- Murata T, Handa H, Mori K, Nakano Y (1981): The significance of periventricular lucency on computed tomography: Experimental study with canine hydrocephalus. *Neuroradiology*, 20, 221–227.
- Nykamp S, Scriveri P, DeLahunta A, Yu-Speight A, Rus R (2001): Chronic subdural hematomas and hydro-

- cephalus in a dog. *Veterinary Radiology and Ultrasound*, 42, 511–514.
- Oi S, Kudo H, Yamada H, Kim S, Hmano S, Urui S, Matsumoto S (1991): Correlation of hydromyelia with various stages of hydrocephalus in postshunt isolated compartments. *Journal of Neurosurgery*, 74, 371–379.
- Oi S, Honda Y, Hidaka M, Sato O, Matsumoto S (1998): Intrauterine high-resolution magnetic resonance imaging in fetal hydrocephalus and prenatal estimation of postnatal outcomes with “perspective classification”. *Journal of Neurosurgery*, 88, 685–694.
- Tarnaris A, Kitchen ND, Watkins LD (2009): Noninvasive biomarkers in normal pressure hydrocephalus: evidence for the role of neuroimaging. *Journal of Neurosurgery*, 110, 837–851.
- Vullo T, Korenman E, Manzo RP, Gomez DG, Deck MDE, Cahill PT (1997): Diagnosis of cerebral ventriculomegaly in normal adult beagles using quantitative MRI. *Veterinary Radiology and Ultrasound*, 38, 277–281.

Received: 2009–08–24

Accepted after corrections: 2010–03–19

Corresponding Author:

Bo-Young Choe, Ph.D., The Catholic University of Korea, College of Medicine, Research Institute of Biomedical Engineering, Department of Biomedical Engineering, #505 Banpo-Dong, Seocho-Gu, Seoul 137-701, Republic of Korea
Tel. +822 2258 7233, Fax +822 2258 7760, E-mail: bychoe@catholic.ac.kr
