

## Tests for the presence of koi herpesvirus (KHV) in common carp (*Cyprinus carpio carpio*) and koi carp (*Cyprinus carpio koi*) in the Czech Republic

D. POKOROVA<sup>1</sup>, V. PIACKOVA<sup>2</sup>, A. CIZEK<sup>3</sup>, S. RESCHOVA<sup>1</sup>, J. HULOVA<sup>1</sup>,  
M. VICENOVA<sup>1</sup>, T. VESELY<sup>1</sup>

<sup>1</sup>Veterinary Research Institute, Brno, Czech Republic

<sup>2</sup>University of South Bohemia, Ceske Budejovice, Research Institute of Fish Culture and Hydrobiology, Vodnany, Czech Republic

<sup>3</sup>University of Veterinary and Pharmaceutical Sciences, Brno, Czech Republic

**ABSTRACT:** An outbreak of koi herpesvirus (KHV) infection associated with high mortality of common and koi carp was recorded in the USA and Israel in 1998. At present, this disease is viewed as one of the most significant factors that can adversely affect common and koi carp breeds. The disease has spread worldwide including European countries neighbouring with the Czech Republic (CR), i.e. Germany, Poland, and Austria. To monitor the situation in the CR, samples were collected from a total of 138 common and koi carps in seven and eight locations in CR respectively, and were examined between 2005 and 2006. Locations owned by the major producers of common and koi carp were selected with respect of potential occurrence of the KHV virus. No records of increased mortality and morbidity were noticed there. Preferentially carps with non-specific symptoms of disease were sampled, often with isolated skin erosions. To obtain detailed picture about health condition of examined fish the bacteriological and haematological examinations were accomplished. The next part of the examined samples were carp and koi carp for export from professional breeders, imported koi carp and fish from breeds with increased mortality (45 and 21 fish in 2005 and 2006, respectively) The only virological testing was done in this case. The culture and PCR method, according to Gilad et al. (2002) showed negative results for virus KHV in all years. Retrospective investigation by PCR method according to Bercovier et al. (2005) showed positivity in five locations in 2005. In 2006, KHV virus was not detected in any of the selected locations. The aim of our study was to find out the presence/absence of KHV in selected locations and potential correlation of virological, bacteriological and haematological findings. The results of first testing for presence of koi herpesvirus indicates the necessity of regular KHV monitoring in the Czech Republic in the next period.

**Keywords:** koi; common carp; herpesvirus; koi herpesvirus (KHV)

Common carp (*Cyprinus carpio carpio*) is a worldwide the most frequent fish species kept above all in Asian and European countries. Koi carp (*Cyprinus carpio koi*) is raised all over the world, especially in Japan, as an ornamental variety of common carp (Balon, 1995). In 1998, high mortality erupted in common and koi carp in the USA and Israel. Retrospective studies showed that the

disease affected common carp in the UK as early as in 1996 (Bretzinger et al., 1999; Hedrick et al., 1999, 2005). These outbreaks were due to a deadly infection with a newly recognized virus, the koi herpesvirus (KHV). KHV infection caused 80–90% mortality in all registered cases of common and koi carp (Hedrick et al., 2000; Gilad et al., 2003; Hutoran et al., 2005). Fish die of general emaciation

Supported by the Ministry of Agriculture of the Czech Republic (Grant No. MZe 1B44016 and MZe 0002716201).

and respiratory problems. External signs of KHV infection may include gill mottling with red and white patches and increased mucus production. Internal signs of KHV may include mottled appearance of livers and other gross lesions (Walster, 1999; Hedrick et al., 2000). The affected carp populations are susceptible to a variety of non-specific bacterial, fungal and parasitic infections (Bretzinger et al., 1999; Hedrick et al., 2000; Perelberg et al., 2003). Haematological tests showed diverse osmoregulatory dysfunctions, hypoproteinaemia, hepatic dysfunction and noticeable immunosuppression. Intranuclear inclusions were found in histological sections (Tinman and Bejerano, 2000).

Koi herpesvirosis is highly contagious to fish and may cause significant morbidity and mortality solely in common and koi carp (Perelberg et al., 2003, 2005). The disease regularly appears in the spring and autumn months indicating that the virus is associated with specific temperature conditions in nature, i.e. with water temperature between 18 and 28°C (Ronen et al., 2003; Perelberg et al., 2005). The virus spreads as a result of worldwide trade in live koi carp. So far the virus has been identified in European countries, Indonesia, South Africa, Thailand, Taiwan, Japan, China and Malaysia (Haenen et al., 2004; Sano et al., 2004). In 1997 the first outbreak of the infection was recorded in Germany (Bretzinger et al., 1999), in 2001 two positive samples from fish imported from Poland to Germany were confirmed (Bergmann et al., 2006), and in 2003 infection in Austria was reported (Haenen et al., 2004). These are neighbouring countries of the Czech Republic, which is one of the world biggest producers of cyprinids. At present, ornamental fish trade has expanded into the Czech Republic, especially with koi carp; and this contributes to the risk of virus transmission, which can adversely affect production of common carp for human consumption. Therefore in 2005 monitoring of common and koi carp was initiated in the Czech Republic. The obtained results are presented in this study.

## MATERIAL AND METHODS

### Fish

During the two-year monitoring period, a total of 204 samples were examined for the presence of KHV. In total 138 carp and koi carps were sampled

between May and July, when the water temperature reached at least 18°C, from seven and eight locations in 2005 and 2006, respectively. Common and koi carp farms were selected for sampling with respect of potential occurrence of the KHV virus, i.e. locations with imported fish or locations with an occurrence of non-specific clinical symptoms of the disease. The following farms were preferentially selected: Koi carp farms (four farms in 2005, five farms in 2006) and big fishing companies (three farms) dealing with market carp production. No records of increased mortality and morbidity were noticed there. Due to the fact that mortality related to KHV disease typically occurs at water temperatures between 18–28°C (Gilad et al., 2003), the fish were kept in a 14-day quarantine at the temperature of 23°C before sampling in 2006. Furthermore, samples from different locations were included in the virological screening on request to confirm absence of the KHV virus in koi carp for exportation, or in imported koi carp and from owners with increased mortality of carp – 45 and 21 samples during the year 2005 and 2006, respectively.

### Virological testing

#### Sample collection for virological testing.

Individual samples of hepatopancreas, cranial kidney, spleen and gills were collected from fish. After dilution with culture medium (1:5), organ homogenates from each fish were centrifuged and a part of supernatant was used for nucleic acid extraction for PCR virus detection. The next part of supernatant was mixed with supernatant of another individual fish samples from the same location and these pooled samples of 10 fish were prepared for culture in cell lines. The samples were stored for 24 h in a refrigerator before inoculation.

**Cell cultures and virus.** Tissue homogenates from tested fish were inoculated onto two fish cell lines: the koi fin (KF-1) from epithelial tissues of koi carp (Hedrick et al., 2000) for isolation of KHV and the epithelioma papulosum cyprini (EPC) from common carp (Fijan et al., 1983) for isolation of other possible viruses of carp. Both cell lines were propagated at 25°C in minimal essential medium with Earle's salts (E-MEM/HEPES) supplemented with 10% foetal bovine serum (FBS), 50 IU penicillin/ml, 50 µg streptomycin/ml, and 2mM L-glutamine. One-day old cell lines were inoculated with 0.7 ml of tissue homogenate and after the adsorp-

tion period of 1 h, medium with 2% FBS was added to each flask, placed at 20°C and observed daily for evidence of cytopathic effects (CPE). The subculture was performed 20 days later.

**Preparation of positive control for PCR assay.** The KHV virus, provided by the Friedrich-Loeffler Institute, Insel Riems, was propagated in KF-1 cell line (Hedrick et al., 2000). After CPE detection, i.e. 7 to 14 days after inoculation of the virus on the cells, the cells were gently centrifuged (3 000 × g, 15 min). To confirm the herpesvirus presence, the supernatant was analyzed by electron microscopy (EM), and then administered intraperitoneally to koi carp. Pooled samples of organs (hepatopancreas, cranial kidney, spleen) and gills were collected from dead carps. After DNA extraction, samples were analysed by the PCR method and used as a positive control.

**DNA extraction.** The medium harvested from the cells infected with a pooled homogenate and tissue homogenate prepared from each separate fish were used for DNA isolation. The nucleic acid extraction was performed by QIAamp Viral DNA Kit (Qiagen, Hilden, Germany) following the manufacturer's instructions. Total DNA obtained from 200 µl of tested material was dissolved in DNase and RNase – free water and subsequently used in PCR.

**PCR assay.** Two primers pairs were used in this study. The first one F 5'-GAC GAC GCC GGA GAC CTT GTG -3' / R 5'-CAC AAG TTC AGT CTG TTC CTC AAC -3' designed by Gilad (Gilad et al., 2002) were used for PCR detection of virus. The second primer pair, designed by Bercovier (Bercovier et al., 2005): F 5'-GGG TTA CCT GTA CGA G -3' / R 5'-CAC CCA GTA GAT TAT GC -3'. The size of amplification product was 484 bp and 409 bp, respectively. The cycling conditions consisted of 94°C/5 min, followed by 35 cycles of one minute intervals at 95°C, 55°C, 72°C and finally extension was performed at 72°C/10 min. Positive control was prepared from tissue homogenates from koi carp experimentally infected with KHV and was examined with each group of analysed samples. PCR products were separated on a 1% agarose gel containing ethidium bromide and visualised by UV.

### Haematological testing

**Blood test.** Standard ichthyohaematological methods, according to Svobodova et al. (1991), were used

for the collection and processing of blood samples. Before blood sampling, fish were anaesthetised in 0.3 ml/l of 2-phenoxyethanol solution. After the onset of anaesthesia, blood samples were drawn from the caudal vein using a heparinised needle and syringe. The following haematological parameters were determined: red blood cell count (RBC; T/l), white blood cell count (WBC; G/l), differential leukocyte count (DIF; %), hematocrite (PCV; l/l), haemoglobin concentration (Hb; g/l) mean cell haemoglobin concentration (MCHC; l/l), mean cell haemoglobin (MCH; pg), and mean corpuscular volume (MCV; fl).

**Biochemical analysis of blood plasma.** Blood plasma was obtained by centrifugation of blood samples at 2 000 × g for 10 min. Individual samples of plasma were stored in a freezer at –80°C. Concentrations of total protein (TP), albumin (ALB), globulin (GLOB), glucose (GLU), aspartataminotransferase (AST) and alaninaminotransferase (ALT) were determined in plasma using blood analyzer VETTEST 8008 (IDEXX Laboratories Inc., USA).

**Bacteriological investigation.** Aseptically collected tissues from parenchymatous organs (hepatopancreas, kidney), gill swabs and skin swabs from euthanised fish were cultured for isolation of *Aeromonas* spp. and for isolation of *Flavobacterium* sp. If ulcerous lesions were found on the skin of slaughtered fish, swabs were taken preferentially from these sites.

Selective agars for *Aeromonas* spp. and *Flavobacterium* spp. isolation were incubated at 30°C or at 25°C for 48 h, respectively. The obtained bacterial cultures were pre-identified according to morphology of colonies, microscopic examination, production of catalase and oxidase and resistance to vibriostatic agent O/129 (Rahman et al., 2002). In the genus *Flavobacterium*, testing for the presence of *Flavobacterium columnare* species was performed because of its ability to cause koi carp gill necrosis (Decostere et al., 2002). The extent of bacteriological findings in respective samples was expressed by plus symbols showing growth intensity. Bacterial growth into the first isolation segment was expressed by +, into the second, third and fourth isolation segment by ++, +++ and +++++, respectively.

### RESULTS AND DISCUSSION

Over the two-year period, samples from common and koi carp from selected locations were collected

during the spring months. Due to the fact that some authors described a presence of secondary bacterial pathogens in fish infected with KHV (Haenen et al., 2004) and some differences in haematological tests (Tinman and Bejerano, 2000), obtained samples were also examined for the presence of bacteria and biochemical parameters of blood and plasma. Virological examination consisted of inoculation of homogenates prepared from pooled organs and gills of fish from one location onto EPC and KF-1 cell lines. Whilst control koi herpesvirus produced CPE on a KF-1 cell line on Day 7 after inoculation, tissue samples obtained from carps in 2005 and 2006 did not show any CPE on KF-1 cell line even after the subcultivation. Isolation of virus was successful in the case of location 02/05 only, which showed CPE on EPC cell line after the first passage. The ELISA test (Rodak et al., 1993) and RT-PCR method (Koutna et al., 2003) detected the spring viraemia of carp (SVC) virus in this sample. In two fish from this location pathogenic species of *Flavobacterium* genus, *F. columnare*, was detected. In this location average haemoglobin concentration (Hb; 51.9 g/l) and associated average values of mean cell haemoglobin (MCH; 42.3 pg) and mean cell haemoglobin concentration (MCHC; 0.16 l/l) were slightly decreased. Concentration of total protein was slightly decreased too (18 g/l).

Pooled samples of fish tissues and gills were examined by PCR for KHV virus detection according to Gilad et al. (2002). All the samples examined were negative by this method, including samples obtained by passage of pooled homogenates on KF-1 cell lines. Late in 2006, PCR method according to Bercovier et al. (2005) was implemented into our

laboratory. Unfortunately, only frozen samples after the subcultivation on KF-1 cell line from 2005 and 2006 were available and were therefore tested by this protocol. Pooled homogenate samples after the subcultivation on KF-1 cell line from 2005 showed positivity for locations 01/05, 03/05, 04/05, 05/05 and 06/05 (Figure 1).

Unfortunately, due to the retrospective use of the PCR according to Bercovier et al. (2005) on pooled samples only, we were unable to correlate bacteriological and haematological samples from individual fish with PCR results of particular fish (Table 1). Despite this it does not appear that any correlation could be observed since all the haematological parameters, except of fish infected with SVCV, were within physiological ranges. As far as bacteriological findings are concerned, gills and skin of fish were massively colonised with bacteria of the genera *Aeromonas* and *Flavobacterium*, especially in the site of skin erosions. The degree of colonisation differed between respective groups and between respective fish within a group regardless of virological results.

Fish samples delivered by breeders with the purpose to ascertain KHV virus presence in koi carp intended for exportation and imported carp were negative by cultivation and PCR method.

With regard to an outbreak situation in neighbouring countries, KHV virus occurrence can also be expected in the CR (Pokorova et al., 2005). Initially, from negative results of a two-year surveillance project for common and koi carp farms from selected locations, CR appeared free from this infection. Introduction of the PCR method according to Bercovier et al. (2005), and retrospective

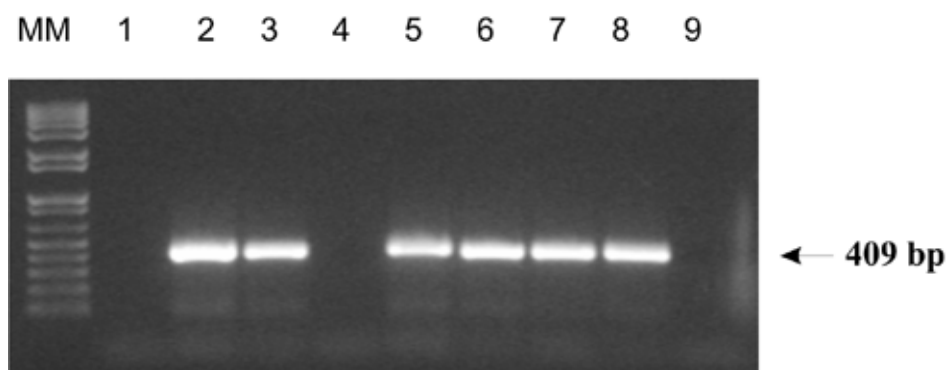


Figure 1. Investigation of pooled samples in 2005 by PCR assay using KHV-TK primers according to Bercovier et al., 2005

Lane 1 = without template, lane 2 = positive control, lanes 3–9 = PCR products of DNA templates (localities 01/05–07/05), MM = molecular marker (TrackIt™ 1 kb Plus DNA Ladder)

Table 1. Summarised results of virological and bacteriological examination of samples collected in respective locations in a year 2005 and 2006

Location No.	PCR Gil/Ber	Gill swabs	Skin swabs (number of swabs from skin erosions)	Parenchymatous organs
01/05C	-/+	A +++ to ++++* F ++ to ++++	(10)#, A +++ to ++++ F +++ to ++++	0**
02/05C	-/-	A +++ to ++++ F ++ to ++++	(8), A +++ to ++++ F ++ to ++++ 2 × FC +++	7 × hepatopancreas with finding A ++++ 1 × FC +
03/05C	-/+	A + to +++ F + to ++++	(0), A + to ++++ F 0	2 × hepatopancreas with finding A +++ to ++++
04/05K	-/+	A + to +++ F - 0	(8), A + to ++++ F 0	0
05/05C	-/+	A +++ to ++++ F ++ to ++++	(3), A +++ to ++++ F +++ to ++++	0
06/05C	-/+	A +++ to ++++ F ++ to ++++	(9), A +++ to ++++ F +++ to ++++	0
07/05C	-/-	A +++ to ++++ F + to ++	(0), A +++ to ++++ F + to +++	2 × hepatopancreas and kidney with finding A ++++
01/06K	-/-	A + to +++ F 0 to +	(0), A +++ to ++++ F + to +++	0
02/06K	-/-	A + to ++ F 0	(5), A + to +++ F 0	0
03/06K	-/-	A ++ to +++ F + to ++	A ++ to +++ F + to +++	1 × hepatopancreas and kidney A ++++
04/06K	-/-	A + to ++++ F + to ++++	(0), A + to ++++ F ++ to ++++	1 × hepatopancreas, spleen and kidney with finding A ++++, F ++++
05/06K	-/-	A +++ F ++ to +++	(2), A + to +++ F ++ to +++	2 × hepatopancreas, spleen and kidney with finding A ++ to ++++, F 0 to +
06/06C	-/-	ND	ND	ND
07/06C	-/-	A + to +++ F +	(0), A + to ++ F +	2 × hepatopancreas, 3 × spleen with finding A +++ to ++++, F 0
08/06C	-/-	A ++ to ++++ F ++ to +++	(0), A +++ to ++++ F ++ to ++++	4 × hepatopancreas, 2 × kidney, 1 × spleen with finding A +++ to ++++, F 0

01/05–07/05 = number of sample/year of sampling

Gil = primers according to Gilad et al., 2002; Ber = primers according to Bercovier et al., 2005

A = *Aeromonas* spp., F = *Flavobacterium* spp., FC = *Flavobacterium columnare*

<sup>K</sup>*Cyprinus carpio koi*, <sup>C</sup>*Cyprinus carpio carpio*

\*growth intensity expressed by plus symbols means 75 to 100%

\*\*non-significant finding

#number of swabs from skin erosions

analysis of samples originally considered negative, revealed positivity of pooled samples of tissue and gill homogenates in five selected locations in 2005. Since we did not observe any significant clinical signs of the disease in the positive location, the level of virus infection is probably quite low. In view of the fact that KHV may be a factor causing high morbidity and mortality both in common and

koi carp (Hedrick et al., 2000) and due to positive findings in neighbouring European countries (Haenen et al., 2004; Bergmann et al., 2006), the regular monitoring in the Czech Republic seems to be necessary. Monitoring would result in efficient data collection and allow control the spread of the infection by imposing effective protective measures.

## Acknowledgements

The authors are grateful to I. Halikova, L. Leharova and J. Martinu (Veterinary Research Institute, Brno, Czech Republic) for technical assistance.

## REFERENCES

- Balon E.K. (1995): Origin and domestication of the wild carp, *Cyprinus carpio* – from Roman gourmets to the swimming flowers. *Aquaculture*, 129, 3–48.
- Bercovier H., Fishman Y., Nahary R., Sinai S., Zlotkin A., Eyngor M., Gilad O., Eldar A., Hedrick R.P. (2005): Cloning of the koi herpesvirus (KHV) gene encoding thymidine kinase and its use for a highly sensitive PCR based diagnosis. *BMC Microbiology*, 5, 13.
- Bergmann S.M., Kempter J., Sadowski J., Fichtner D. (2006): First detection, confirmation and isolation of koi herpesvirus (KHV) in cultured common carp (*Cyprinus carpio* L.) in Poland. *Bulletin of the European Association of Fish Pathologists*, 26, 97–104.
- Bretzinger A., Fischer-Scherl T., Oumouna M., Hoffmann R., Truyen U. (1999): Mass mortalities in koi carp, *Cyprinus carpio*, associated with gill and skin disease. *Bulletin of the European Association of Fish Pathologists*, 19, 182–185.
- Decostere A., Ducatelle R., Haesebrouck F. (2002): Flavobacterium columnare (*Flexibacter columnaris*) associated with severe gill necrosis in koi carp (*Cyprinus carpio* L.). *Veterinary Record*, 150, 694–695.
- Fijan N., Sulimanovic D., Bearzotti M., Muzinic D., Zwilenberg L.O., Chilmoneczyk S., Vautherot J.F., Dekinkelin P. (1983): Some properties of the epithelioma papulosum cyprini (Epc) cell-line from carp *Cyprinus carpio*. *Annales de Virologie*, 134, 207–220.
- Gilad O., Yun S., Andree K.B., Adkison M.A., Zlotkin A., Bercovier H., Eldar A., Hedrick R.P. (2002): Initial characteristics of koi herpesvirus and development of a polymerase chain reaction assay to detect the virus in koi, *Cyprinus carpio koi*. *Diseases of Aquatic Organisms*, 48, 101–108.
- Gilad O., Yun S., Adkison M.A., Way K., Willits N.H., Bercovier H., Hedrick R.P. (2003): Molecular comparison of isolates of an emerging fish pathogen, koi herpesvirus, and the effect of water temperature on mortality of experimentally infected koi. *Journal of General Virology*, 84, 2661–2668.
- Haenen O.L.M., Way K., Bergmann S.M., Ariel E. (2004): The emergence of koi herpesvirus and its significance to European aquaculture. *Bulletin of the European Association of Fish Pathologists*, 24, 293–307.
- Hedrick R.P., Marty G.D., Nordhausen R.W., Kebus M. J., Bercovier H., Eldar A. (1999): A herpesvirus associated with mass mortality of juvenile and adult koi *Cyprinus carpio*. *Fish Health Newsletter*, 27, 7.
- Hedrick R.P., Gilad O., Yun S., Spangenberg J.V., Marty G.D., Nordhausen R.W., Kebus M.J., Bercovier H., Eldar A. (2000): A herpesvirus associated with mass mortality of juvenile and adult koi, a strain of common carp. *Journal of Aquatic Animal Health*, 12, 44–57.
- Hedrick R.P., Gilad O., Yun S., McDowell T.S., Waltzek T.B., Kelly G.O., Adkison M.A. (2005): Initial isolation and characterization of a herpes-like virus (KHV) from koi and common carp. *Bulletin of Fisheries Research Agency*, 2, 1–7.
- Hutoran, M., Ronen, A., Perelberg, A., Ilouze, M., Dishon, A., Bejerano, I., Chen, N., Kotler, M. (2005): Description of an as yet unclassified DNA virus from diseased *Cyprinus carpio* species. *Journal of Virology*, 79, 1983–1991.
- Koutna M., Vesely T., Psikal I., Hulova J. (2003): Identification of spring viraemia of carp virus (SVCV) by combined RT-PCR and nested PCR. *Diseases of Aquatic Organisms*, 55, 229–235.
- Perelberg A., Smirnov M., Hutoran M., Diamant A., Bejerano Y., Kotler M. (2003): Epidemiological description of a new viral disease afflicting cultured *Cyprinus carpio* in Israel. *Israeli Journal of Aquaculture, Bamidgeh*, 55, 5–12.
- Perelberg A., Ronen A., Hutoran M., Smith Y., Kotler M. (2005): Protection of cultured *Cyprinus carpio* against a lethal viral disease by an attenuated virus vaccine. *Vaccine*, 23, 3396–3403.
- Pokorova D., Vesely T., Piackova V., Reschova S., Hulova J. (2005): Current knowledge on koi herpesvirus (KHV): a review. *Veterinarni Medicina*, 50, 139–147.
- Rahman M., Colque-Navarro P., Kuhn I., Huys G., Swings J., Mollby R. (2002): Identification and characterization of pathogenic *Aeromonas veronii* biovar *sobria* associated with epizootic ulcerative syndrome in fish in Bangladesh. *Applied and Environmental Microbiology*, 68, 650–655.
- Rodak L., Pospisil Z., Tomanek J., Vesely T., Obr T., Valicek L. (1993): Enzyme-linked-immunosorbent-assay (Elisa) for the detection of spring viremia of carp virus (SVCV) in tissue-homogenates of the carp, *Cyprinus carpio* L. *Journal of Fish Diseases*, 16, 101–111.
- Ronen A., Perelberg A., Abramowitz J., Hutoran M., Timan S., Bejerano I., Steinitz M., Kotler M. (2003): Efficient vaccine against the virus causing a lethal disease in cultured *Cyprinus carpio*. *Vaccine*, 21, 4677–4684.
- Sano M., Ito T., Kurita J., Yanai T., Watanabe N., Miwa S., Iida T. (2004): First detection of koi herpesvirus in

- cultured common carp *Cyprinus carpio* in Japan. Fish Pathology, 39, 165–167.
- Svobodova Z., Pravda D., Palackova J. (1991): Unified methods of haematological examination of fish (in Czech). Manuals of Research Institute of Fish Culture and Hydrobiology, University of South Bohemia, Vodnany, 22, 31 pp.
- Tinman S., Bejerano I. (2000): Field observations of a herpes viral disease of koi carp (*Cyprinus carpio*) in Israel. In: Book of Abstract of the 24<sup>th</sup> Annual Israel Veterinary Symposium, April 17, 2000, Hebrew University of Jerusalem.
- Walster C. (1999): Clinical observations of severe mortalities in koi carp, *Cyprinus carpio*, with gill disease. Fish Veterinary Journal, 3, 54–58.

Received: 2007–06–14

Accepted after corrections: 2007–10–18

---

Corresponding Author:

Tomas Vesely, Veterinary Research Institute, Hudcova 70, 621 00 Brno, Czech Republic  
Tel. +420 533 331 112, fax +420 541 211 229, e-mail: vesely@vri.cz

---