

Gynaecomastia in a tom-cat caused by cyproterone acetate: a case report

F. JELINEK¹, R. BARTON², J. POSEKANA², L. HASONOVA³

¹Veterinary Histopathological Laboratory, Prague, Czech Republic

²Veterinary Clinic of Small Animals, Ceske Budejovice, Czech Republic

³Faculty of Agriculture, University of South Bohemia, Ceske Budejovice, Czech Republic

ABSTRACT: The contribution demonstrates gynaecomastia in an adult, noncastrated tom-cat, caused by an antiandrogenic preparation Androcur tablets (Schering AG, BRD), administered at the dose of 5 mg/day for one week. Two months after the treatment, the enlargement of all mammary glands was apparent and one month later (i.e. three months after the end of drug administration) the mammary chains reached the size of 30 × 15 × 20 cm. The general health state of the animal was altered due to the conspicuous enlargement and inflammation of mammary glands. Radical mastectomy was done under general anaesthesia using Isoflurane Rhone-Poulenc inh. The weight of the extirpated mammary chains was 1.75 kg. The healing of operative wounds and convalescence occurred without complications. Fibroepithelial hyperplasia of mammary glands was diagnosed histologically.

Keywords: tom-cat; gynaecomastia; Androcur

The sexual activity of intact male cats manifests itself by a urine spraying of the territory that is unpleasant, especially when the cat is kept indoors (Dolezel et al., 2001). This behaviour can be eliminated substantially by means of surgical castration. Because this is permanent, in males of rare breeds a provisional and reversible depression of sexual behaviour is preferred. For these reasons progestins are recommended in the veterinary literature (e.g. medroxyprogesterone acetate, melengesterol acetate and megestrol acetate) (Romagnoli and Concannon, 2003). Treatments with megestrol acetate (Megace, Bristol-Myers Squibb) at a dosage of 2.5–5.0 mg *pro toto* for seven days or amitriptylin (Amitriptylin, Slovakofarma, Slovak Republic) at 5.0–10.0 mg *pro toto* (Zertova, 2001) were recommended. The administration of these progestins was associated with mammary fibroepithelial hyperplasia (Hinton and Gaskell, 1977; Betlehem and van der Luer, 1993; De Souza, 2002; MacDougall, 2003; Loretto et al., 2005).

In the reported case the owner of the cat used Androcur tablets 50 mg (Schering AG, BRD), which

is an antiandrogenic drug used in human medicine. The effective substance of the tablets is cyproterone acetate, which is a steroid antiandrogen that specifically blocks the effects of androgens at the target organs including the central nervous system by means of competitive inhibition of 5- α -dihydrotestosterone binding to the cytosol receptors of the cell. In humans Androcur is used in men to reduce the sex drive in sexual deviates. It is also used for a treatment of inoperable carcinoma of the prostate gland, in women it is used to subdue signs of androgenisation (hirsutism, alopecia), and in children it is used to treat idiopathic pubertas praecox (Heresova, 2003). The drug has several side-effects: in men it can cause reversible inhibition of spermatogenesis, impotency and gynaecomastia, in women it can cause ovarian disorders (Suchopar, 1997). Neither Androcur nor other cyproterone acetate based drugs are registered for veterinary use. However, in the community of cat fanciers the drug is known as “tom-cat contraception” and is used to prevent the sexual activity of tom-cats that are not old enough to undergo castra-

tion, or in cats whose owners refuse to have their pet castrated. The drug is also allegedly used during exhibitions to calm down tom-cats and make them more tractable.

MATERIAL AND METHODS

A British shorthair tom-cat, two years old, 6.45 kg, uncastrated, was kept in a household together with several female cats. In order to suppress the tom-cat's sexual behaviour, Androcour drug was administered to him by the owner. The drug was administered in a dose of 1/10 of the tablet (50 mg cyproterone acetate) per day for one week. After a few days the tom-cat stopped the urine spraying of the territory, and did not manifest any sexual interest in female cats. Two months after the end of the treatment the mammary glands of the tom-cat began to enlarge. Three months after the end of the treatment the mammary chains reached the size of 30 × 15 × 20 cm (Figure 1 and 2). The general health state of the animal was altered and anorexia and polydipsia were noted.

Clinical examination revealed a rectal temperature of 39.7°C; the pulse rate and respiratory rate were normal. The mucous membranes were slightly pale and the CRT was two seconds.

The other organs, other than the mammae, appeared normal. The mammary chains were algesic, stiff and nodular, and they appeared warm to the touch. The medial linea was not visible. The skin overlying the

Table 1. Haematological and biochemical parameters

Parameter	Results	Range
Erythrocytes (T/l)	9.68	5–10
Leukocytes (G/l)	21.2	7–17
Haemoglobin (g/l)	150	80–150
Hematocrit (l/l)	0.40	0.24–0.45
Thrombocytes (G/l)	598	300–600
Lymphocytes (G/l)	6.2	1–6
Monocytes (G/l)	0.023	0.0–0.06
Eosinophils (G/l)	0.25	0.0–0.9
Basophils (G/l)	0.0	0.0–0.1
ALP (U/l)	63	10–90
ALT (U/l)	69	20–100
Urea (mmol/l)	4	3.6–10.7
Globulin (g/l)	40	15–57
Creatinine (μmol/l)	87	27–141
Glucose (mmol/l)	6.2	3.9–8.3

Reference range: Doubek et al. (2001)

mammae was thinner and some areas were alopecic. Purulent secretion and crusts were apparent at several areas. The results of biochemical and haematological investigations are shown in Table 1.

Gynaecomastia complicated by inflammation was clinically diagnosed. With respect to the actual

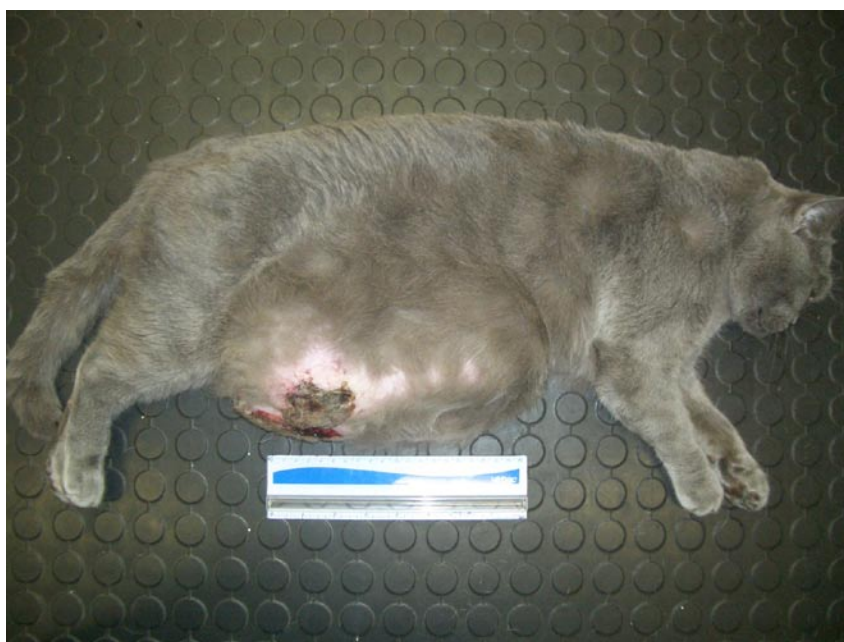

Figure 1. A two-years-old tom-cat (British shorthair) with feline mammary fibroepithelial hyperplasia

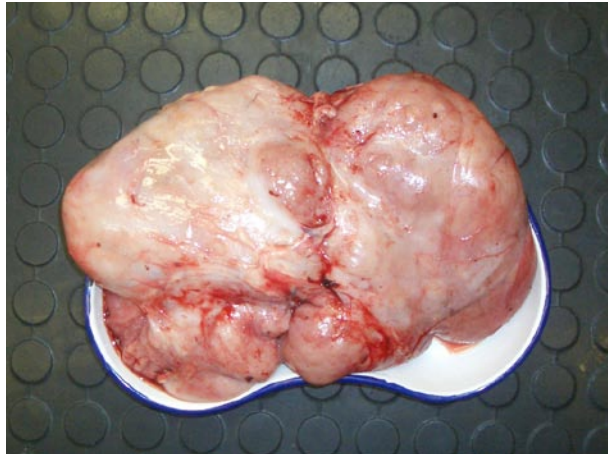


Figure 2. Exstirpated mammary chains

health state radical mastectomy (after a previous anti-inflammatory drug treatment) was the only therapeutic method of choice. For treatment of inflammation in the hyperplastic mammary glands and for prevention of general infection amoxicilinum with acidum clavulanatum (Synulox Pfizer) was administered in a dose 12.5 mg/kg of body weight per day for three days before the operation, and carprofenum (Rimadyl Pfizer) in a single dose of 4 mg/kg of body weight was administered as well. This medication slightly improved the health state of the patient. The radical mastectomy was done in general anaesthesia using an inhalation anaesthetic isoflurane 2.5%. During the operation Ringer solution was applied intravenously at a quantity of 50 ml/hour, in the total dose of 250 ml. The surgical incision in the laurel shape was conducted into both mammary chains, and using a blunt preparation the mammae were separated from the skin, fascia and muscles. Vessels supplying the mammae were conspicuously dilated and therefore the larger vessels were ligated, and venous bleeding was stopped by means of cauterization. After the mastectomy per se a standard suture of subcutaneous connective tissue and skin was done. The operation field was covered by Pruban. Amoxicilinum with acidum clavulanatum (Synulox Pfizer) in a dose 12.5 mg/kg of body weight per day was administered for seven days after the surgery to prevent local and general infection. Convalescence ran quickly and without any complications. On the tenth day after the operation the operation lesion was healed per primam and the tomcat reached full fitness and good nutritional state.

The weight of both extirpated mammary chains was 1.75 kg. The cut surface of the glands was

similar to the mammary gland tissue, however milk secretion was not apparent. Samples from the lesions were excised and examined histologically. The material was processed by the common paraffin technique, and histological sections 6 µm thick were stained with haematoxylin and eosin. In parallel sections actin and vimentin were examined by means of the common immunoperoxidase method. The binding of primary antibodies, Monoclonal Mouse Anti-Human Muscle Actin, clone HHF35 (DakoCytomation, Glostrup, Denmark) and Mouse Monoclonal Antibody Vimentin, clone V9 (Immunotech, Marseille, France), was visualized with LSAB 2 system-AP (DakoCytomation, Glostrup, Denmark) and Fast Red Substrate-Chromogen (DakoCytomation, Glostrup, Denmark).

RESULTS

Fibroadenomatous hyperplasia was diagnosed histologically (Figure 3). Immunohistochemistry demonstrated the strong cytoplasmic positivity of actin in the cells located at the periphery of ductules and in the majority of the interstitial cells (Figure 4). Strong cytoplasmic vimentin positivity was recorded in the cytoplasm of many interstitial cells, situated among the proliferating tubules.

DISCUSSION

Fibroadenomatous hyperplasia of mammary glands is a benign process named by several synonyms in the literature – mammary hypertrophy, fibroadenomatous change, fibroepithelial hypertrophy and feline mammary hypertrophy (Hayden et al., 1981; Misdorp et al., 1999; Misdorp, 2002; Foster, 2007).

It usually appears in young, intact queens, and its origination and development are related to an increased level of progesterone or to the administration of substances having progesterone effects.

E.g. the administration of megestrol acetate to old spayed queens and castrated tom-cats for therapeutic reasons could be complicated by fibroadenomatous hyperplasia of mammary glands. The analysis of 26 cases of mammary hypertrophy revealed that 24 were females and 19 out of them were younger than 1.5 year. Only two were castrated males 2 and 4.5 years old, and both were treated with megestrol acetate before the manifestation of changes in the mammary glands (Hayden et al., 1981).

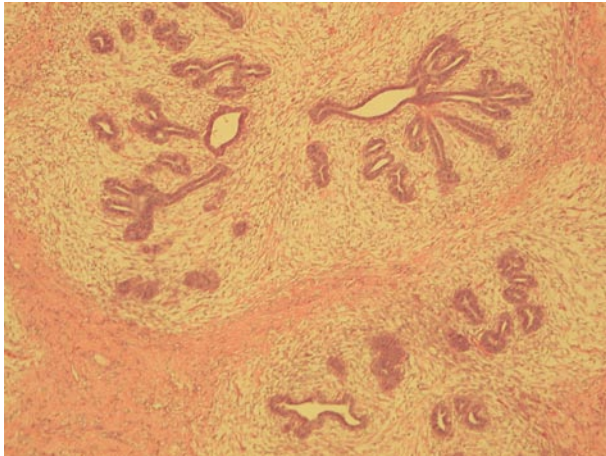


Figure 3. Proliferative ductules surrounded by the abundant loosely arranged stromal tissue. These structures are separated by a strip of the dense collagen tissue. Staining with haematoxylin and eosin, original magnification 20×

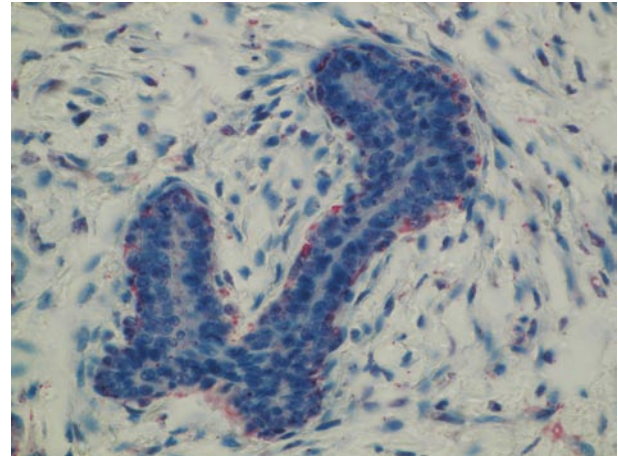


Figure 4. Immunohistochemical detection of actin. Positive (red) are the myoepithelial cells located between cuboidal cells and the basal membrane of tubules. Biotin Labelled Link-Streptavidin-AP, original magnification 160×

Only young females were present in the set of six cases of feline mammary hypertrophy published by Loretto et al. (2005). One case of fibroadenomatous hypertrophy of the mammae in a young castrated male was described by MacDougall (2003).

It is assumed that the growth of mammary tissue is stimulated by a local synthesis of the growth hormone and insulin-like growth factors (IGFs) under the influence of progesterone and progestin-like hormones such as medroxyprogesterone acetate and megestrol acetate (Mol et al., 1996).

Another pathogenetic mechanism could consist in the increased sensitivity of certain cells to the growth stimulating effect of estrogens under the influence of progesterone. It is also possible that prolactin could exert a similar effect. These pathogenetic mechanisms manifest themselves as the proliferation of the epithelium in ductules and stroma of the mammary gland. The majority of glands in the mammary chains are usually affected but the lesions could be visible only in one or two mammae or even as nodules located in one gland.

Haemorrhage, necrosis, ulceration and inflammation can complicate the basic pathological process.

Hayden et al. (1989) diagnosed hyperplastic changes in mammary glands in 14 out of 17 cats treated with of megestrol acetate. Hyperplastic processes consisted of fibroepithelial hyperplasia (nine animals), lobular hyperplasia (three animals) and ductal ectasia (two animals). Tumours were diagnosed in the three remaining animals – adenoma in one case, and carcinoma in the other

cases. However, the authors showed a causal relation only between the administration of megestrol acetate and fibroepithelial hyperplasia.

In young queens suffering from fibroepithelial hyperplasia only ovariectomy is reliably effective but in some of them a rarely spontaneous resolution can also occur. In old spayed animals where fibroepithelial hyperplasia is of iatrogenic origin, it is necessary to terminate the administration of the drug and mastectomy is the only therapeutic method to be used in the majority of the cases. Gorlinger et al. (2002), Meisl et al. (2003) and Vitasek and Dendisova (2006) used aglepristone (an inhibitor of the progesterone receptors) to treat fibroepithelial hyperplasia.

Suchopar (1997) reported that cyproterone acetate also had a gestagenic effect. It can therefore be assumed that this effect contributes to the development of fibroepithelial hyperplasia of mammary glands that reached the abnormal size in our case and negatively influenced the general health state of the animal.

A hint to the use of Androcur for a suppression of sexual activity in cats is published on the internet pages of cat-fanciers community. However, with regard to possible complications the administration of this drug to cats cannot be recommended. In the literature available to us, no information about a relationship between the administration of cyproterone acetate and development of fibroadenomatous hyperplasia of the mammary gland in tom-cats was present and therefore we decided to publish this case report.

REFERENCES

- Bethlehem M., van der Luer R.J. (1993): Feline fibroepithelial hyperplasia in 3 castrated tomcats following treatment with progestagens. *Tijdschrift Voor Diergeneeskunde*, 15, 650–652.
- De Souza T.M., Figliere R.A., Langohr I.M., de Barros C.S.L. (2002): Hiperplasia fibroepitelial mamaria em felinos: Cinco casos. *Ciencia Rural*, Santa Maria, 32, 891–894.
- Dolezel R., Vitasek R., Senior D.F. (2001): Disturbances of reproductive system. In: Svoboda M., Senior D.F., Doubek J., Klimes J. (eds.): *Diseases in Dogs and Cats (in Czech)*. 2nd vol. Novico, Czech Small Animal Veterinary Association, Brno. 1253–1357.
- Doubek J., Klimes J., Senior D.F., Kohout P., Benak J., Svoboda M., Svobodova V. (2001): Practices of Laboratory Diagnostic. In: Svoboda M., Senior D.F., Doubek J., Klimes J. (eds.): *Diseases in Dogs and Cats (in Czech)*. 1st vol. Novico, Czech Small Animal Veterinary Association, Brno. 57–86.
- Gorlinger S., Kolostra H.S., van den Broek A., Oklene A.C. (2002): Treatment of fibroadenomatous hyperplasia in cats with alogestone. *Journal of Veterinary Internal Medicine*, 16, 710–713.
- Foster R.A. (2007): Female reproductive system. In: McGavin M.D., Zachary J.F. (eds.): *Pathologic Basis of Veterinary Disease*. 4th ed. Mosby Elsevier, St. Louis, Missouri. 1263–1315.
- Hayden D.W., Johnston S.D., Kisny D.T., Johnson K.H., Barnes D.M. (1981): Feline mammary hypertrophy/fibroadenoma complex: clinical and hormonal aspects. *American Journal of Veterinary Research*, 42, 1699–1703.
- Hayden D.W., Barnes D.M., Johnson K.H. (1989): Morphologic changes in the mammary gland of megestrol acetate-treated and untreated cats: a retrospective study. *Veterinary Pathology*, 26, 104–113.
- Hinton M., Gaskell C.J. (1977): Non-neoplastic mammary hypertrophy in the cat associated either with pregnancy or with oral progestagen therapy. *Veterinary Record*, 100, 277–280.
- Loretti A.P., Ilha M.R.S., Breitsameter I., Faraco C.S. (2005): Clinical and pathological study of feline fibroadenomatous change associated with depot medroxyprogesterone acetate therapy. *Journal of Feline Medicine and Surgery*, 7, 43–52.
- MacDougall L.D. (2003): Mammary fibroadenomatous hyperplasia in a young cat attributed to treatment with megestrol acetate. *Canadian Veterinary Journal*, 44, 227–229.
- Meisl D., Hubler M., Arnold S. (2003): Treatment of fibroepithelial hyperplasia (FEH) of the mammary gland in the cat with the progesterone antagonist Alogestone (Alizine). *Schweizerische Archiv für Tierheilkunde*, 145, 130–136.
- Misdorp W. (2002): Tumors of the mammary gland. In: Meuten D.J. (ed.): *Tumors in Domestic Animals*. 4th ed. Iowa State Press. 575–606.
- Misdorp W., Else R.W., Hellmen E., Lipscomb T.P. (1999): *Histological Classification of Mammary Tumors of the Dog and the Cat*. Armed Forces Institute of Pathology, Washington, D.C. 58 pp.
- Mol J.A., VanGarderen E., Rutteman G.R., Rijnberk A. (1996): New insights in the molecular mechanism of prolactin-induced proliferation of mammary epithelium: induction of the local synthesis of growth hormone (GH) in the mammary glands of dogs, cats and humans. *Journal of Steroid Biochemistry and Molecular Biology*, 57, 67–71.
- Romagnoli S., Concannon P.W. (2003): Clinical use of progestins in bitches and queens: a review. In: Concannon P.W., England G., Verstegen J., Linde-Forsberg C. (eds.): *Recent Advances in Small Animal Reproduction*. International Veterinary Information Service (www.ivis.org), Ithaca, New York, USA. A1206.0903.
- Suchopar J. (1997): *Remedia Compendium*. 2nd publication. Drugs used to therapy of diseases of endocrine system (in Czech). Panax, Praha.
- Vitasek R., Dendisova H. (2006): Treatment of feline mammary fibroepithelial hyperplasia following a single injection of proligestone. *Acta Veterinaria Brno*, 75, 295–297.
- Zertova H. (2001): Disorders of behaviour in dogs and cats. In: Svoboda M., Senior D.F., Doubek J., Klimes J. (eds.): *Diseases in Dogs and Cats (in Czech)*. 2nd vol. Novico, Czech Small Animal Veterinary Association. 1645–1679.

Received: 2007–07–16

Accepted after corrections: 2007–09–06

For colour figures see <http://www.journals.uzpi.cz/web/vetmed>

Corresponding Author:

Prof. MVDr. Frantisek Jelinek, CSc., Veterinary Histopathological Laboratory, Sojovicka 16, 197 00 Prague 9-Kbely
Tel./Fax +420 286 851 765, e-mail: jelinekv@seznam.cz